

A Sinister Cause for Recurrent Syncope: Metastatic Parapharyngeal Space Tumor

Joshua Agilinko, Vaishnevy Ganesh, Annes Ahmeidat, Bhaskar Ram, Muhammad Shakeel

Department of Otolaryngology-Head and Neck Surgery, Aberdeen Royal Infirmary, Aberdeen, United Kingdom

ABSTRACT

Introduction: Metastasis from oropharyngeal squamous cell carcinoma can occur in the parapharyngeal space (PPS). Syncope is an uncommon presentation of parapharyngeal space tumors. This can occur because of the extrinsic compression or infiltration of the carotid sinus or glossopharyngeal nerve. **Aim:** This study aims to raise awareness about this rare condition of recurrent syncope secondary to PPS tumor. We aim to share our knowledge of dealing with such a case focusing on clinical presentation, investigations, and multidisciplinary approach to management. **Case Presentation:** We present a case of a 68-year-old Caucasian male who was admitted to a medical ward with recurrent episodes of syncope. The underlying cause was found to be the extrinsic compression of the left carotid artery from a PPS tumor. The CT scan of the neck raised a suspicion of the left PPS malignancy. It was confirmed on fine-needle aspiration cytology to be a metastatic poorly differentiated squamous cell carcinoma. The patient was managed with best supportive care. **Conclusion:** In a patient presenting with recurrent syncope, PPS tumor-related carotid sinus or glossopharyngeal nerve involvement should be considered. In our patient, the best supportive care was chosen. However, in select patients, cardiac pacing may be required to prevent recurrent syncope so that curative intent treatment can be started.

Key words: Metastasis, oropharyngeal malignancy, parapharyngeal space, syncope

INTRODUCTION

The parapharyngeal space (PPS) is a potential space where head-and-neck tumors can localize. PPS tumors are rare and account for less than 1% of all head-and-neck cancers.^[1]

Compartmentalization of the PPS into pre-styloid and post-styloid spaces allows head-and-neck surgeons to identify the origin of tumors. Pre-styloid PPS tumors are often salivary gland tumors and post-styloid PPS tumors are of neurogenic and vascular origin.^[2]

Syncope is defined as a sudden onset loss of consciousness and muscle strength.^[3] The length of the carotid arteries as these ascend the neck means these can be easily compressed in PPS tumors. Most patients with syncope are managed by

physicians in a medical ward setting. Extrinsic compression of the carotid artery as the underlying cause may not be very high in the list of differential diagnoses in such patients.

The aim of this article is to raise awareness of this rare condition focusing on clinical presentation, examination findings, appropriate investigations including angiography, and ultrasound scan-guided fine-needle aspiration cytology. We also highlight the importance of looking after such patients by a multidisciplinary team including otolaryngologists and palliative care specialists.

CASE REPORT

A 68-year-old male patient presented to the acute medical assessment unit with a 6-week history of 10 kg weight loss, left neck pain, occipital headaches, and reduced oral intake. He

Address for correspondence:

Mr. Muhammad Shakeel, Department of Otolaryngology and Head and Neck Surgery, Aberdeen Royal Infirmary, Foresterhill Road, Aberdeen, AB25 2ZN, United Kingdom.

© 2020 The Author(s). This open access article is distributed under a Creative Commons Attribution (CC-BY) 4.0 license.

collapsed on his way to the ward with loss of consciousness. He was a retired painter and a life-long smoker. The medical history included peripheral vascular disease and a previous non-STEMI. Initial cardiorespiratory and cranial nerves examination was normal.

Two days into his admission, he developed acute confusion, hallucinations, and more frequent, longer-lasting syncopal episodes. ECG and echocardiogram excluded cardiac arrhythmias and structural abnormalities as a cause of the patient's episodes of syncope.

Initially, a CT scan of his head revealed a small focus of high density between right temporal lobe and mid-brain. A CT intracranial angiography confirmed an atheromatous calcification in the left vertebral artery with focal stenosis with no evidence of intracranial aneurysm.

He was subsequently reviewed by ENT surgeons where he reported a 4-week history of sore throat, hoarse voice, and dysphagia to both solids and fluids. On examination, the left lateral pharyngeal wall showed a medial displacement [Figure 1]. There was a 5 cm left upper neck swelling involving the Level II and III [Figure 2]. There were no palpable cervical lymph nodes or any other palpable abnormality in his neck. A flexible pharyngolaryngoscopy revealed a left lateral pharyngeal wall submucosal swelling, left vocal cord palsy, and pooling of saliva in the pharynx [Figure 3].

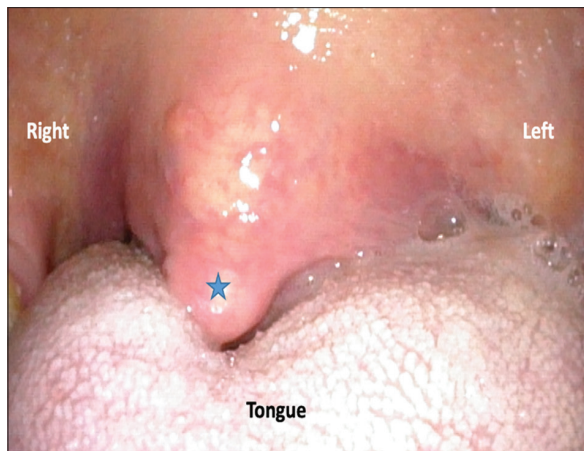

Figure 1: The left lateral pharyngeal wall is enlarged and pushed medially moving the uvula to the right (blue star)

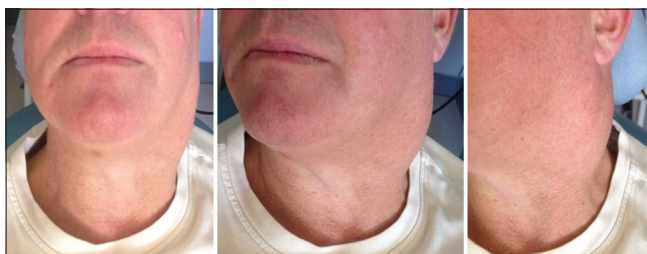

Figure 2: Left upper neck swelling involving the Level II and III

The upper gastrointestinal endoscopy and biopsy revealed esophageal candidiasis for which he was treated with fluconazole.

The CT scan of the neck revealed a large heterogeneous mass lesion with low-attenuated region and septation in the left PPS, displacing left carotid artery, and narrowing of the oropharynx [Figure 4]. A 5 cm cystic heterogeneous mass arising posterior to the common carotid artery and left internal jugular vein was seen on ultrasound scan of his neck.

A needle drainage of the left neck mass was carried out yielding blood-stained yellowish fluid [Figure 5]. The cytological analysis showed cytoplasmic debris with squamoid features and abnormal squamous epithelial cells with hyperchromatic nuclei and cytoplasmic keratinization in keeping with a diagnosis of a metastatic squamous cell carcinoma.

The patient continued to deteriorate and was managed by the palliative care team with best supportive care. The patient died 6 weeks following his diagnosis.

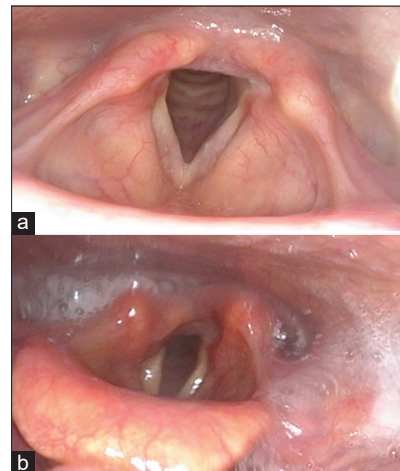


Figure 3: Endoscopic view of the pharynx and larynx showing (a) healthy appearance (b) pooling of saliva

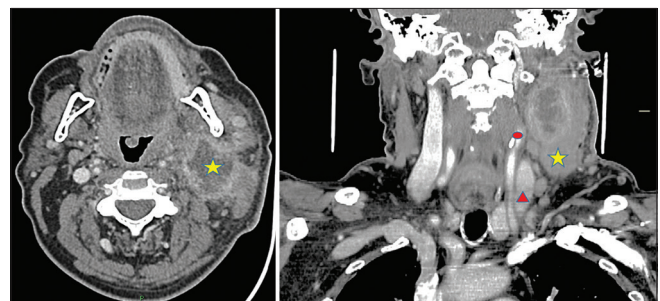


Figure 4: CT scan of the neck showing a large malignant looking mass in the left parapharyngeal space with necrotic center (yellow star) causing extrinsic compression of the left carotid artery (red circle) and internal jugular vein (red triangle)

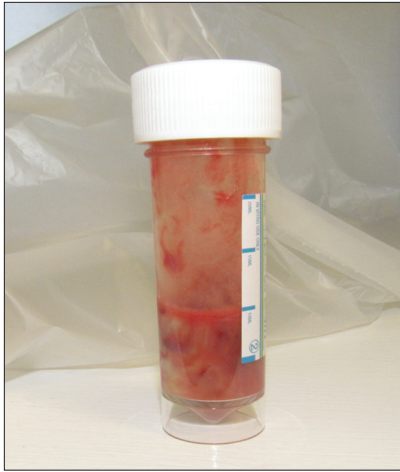

Figure 5: Aspiration of blood-stained necrotic debris from the left neck swelling

DISCUSSION

The PPS is an inverted pyramidal-shaped space in the neck.^[4] It is bounded anteriorly by the pterygomandibular raphe, posterolaterally by the carotid sheath, and posteromedially by the retropharyngeal space. It consists largely of fat and neurovascular structures. One of the key structures contained within the PPS is the carotid artery which passes through the foramen lacerum.

PPS tumors are rare and account for 0.5% of all head and neck cancers. Of these, 20% are malignant.^[1] Oropharyngeal squamous cell carcinoma can metastasize to PPS. Smoking is a major risk factor for developing such cancers. Sexually transmitted diseases including HPV and syphilis have also been implicated.^[5]

Compartmentalization of the PPS into pre-styloid and post-styloid spaces allows head-and-neck surgeons to identify the origin of tumors. Half of the lesions which are located in the pre-styloid PPS are of salivary gland origin.^[2] For lesions in the post-styloid PPS, up to 40% are of neurogenic origin.^[2]

A literature review of 1143 PPS tumors by Riffat *et al.* in 2014 concluded that 50% of PPS lesions are neck masses and 47% are intraoral masses.^[6]

Minkara *et al.* reported the first case of syncope in a 57-year-old male patient with pleomorphic adenoma of the parotid.^[7] Our patient did not have any evidence of parotid or other salivary glands involvement.

The US and CT scans, in combination with biopsy of the mass, are essential in diagnostic work-up of such tumors. Specifically, a CT intracranial angiography allows delineation of any vascular involvement. A carotid body tumor (chemodectoma) can be excluded on this basis.

The right and left carotid arteries originate from different arteries but follow symmetrical courses. The right common carotid artery originates in the neck from the brachiocephalic trunk, the left from the aortic arch in the thorax. The common carotid arteries are major arteries forming the bulk of the Circle of Willis.

Tumors present in the PPS have a potential to cause extrinsic compression of the carotid arteries. This leads to symptoms and signs of carotid sinus syndrome. The underlying pathophysiology is systemic hypotension-brain hypoperfusion phenomenon.^[8] Physiologically, an increase in carotid artery wall pressure causes stimulation of nucleus tractus through the glossopharyngeal nerve. This, in turn, leads to stimulation of cardiac myocytes by vagus nerve to restore homeostasis.^[9] In carotid sinus syndrome, compression of the carotid artery leads to desensitization of the afferent and efferent pathways to the activity of the glossopharyngeal and vagus nerves. Hypotension and bradycardia are, therefore, not well-regulated. When there is already an existing arterial disease such as atherosclerosis, the effect is more pronounced.^[9]

In addition, in patients presenting with syncope, neurological signs and findings of Horner's syndrome should also be investigated for. This is more likely in nasopharyngeal carcinomas with a high propensity for aerodigestive and neurological metastasis. As such, signs such as ptosis, anhydrosis, and miosis should be looked for.^[10]

Oropharyngeal tumors are treated by a combination of surgical resection, radiotherapy, and chemotherapy. Head-and-neck surgeons, oncologists, and radiologists should be aware of the side effects of radiotherapy in patients. The well-known complication of osteoradionecrosis is extensively documented.^[11] In the same way, carotid radioarteritis can occur which may lead to cerebral hypoperfusion and subsequent syncopal episodes.^[12] In severe cases, the arteries can undergo stenosis and occlusion. In patients with diseased carotid and vertebrobasilar system, occlusion of the contralateral side will ultimately lead to cerebrovascular events.^[13]

In a case of a 75-year-old patient with nasopharyngeal cancer presenting with syncope, Zhang *et al.* postulated that, in carotid artery disease, not only is there atherosclerotic non-compliance, there is also generalized autonomic dysfunction. This exacerbates the symptoms and signs of hypotension and bradycardia.^[14] Our patient suffered from recurrent episodes of hypotension refractory to crystalloid as well as colloid fluid resuscitation.

Surgery, chemotherapy, and radiotherapy are treatment options for managing PPS tumors. Our patient was suspected to have primary left oropharynx squamous cell carcinoma. He was not subjected to examination under anesthesia and biopsy because of locally advanced infiltrative PPS metastasis. He

was deemed unfit to undergo any of these treatments. After appropriate counseling of the patient and his family, he was given palliative treatment.

CONCLUSION/LEARNING POINTS

- PPS tumors rarely present with syncopal episodes
- Oropharyngeal squamous cell carcinoma can metastasize to the PPS
- Diagnostic work-up should include angiography of the carotid artery in patients presenting with recurrent episodes of syncope
- Patients presenting with locally advanced and infiltrative malignant lesions in the PPS may be incurable and best supportive care may be the only treatment option in certain patients.

DECLARATION

The photos in this case report are taken from our collection to explain the findings in the patient discussed.

ACKNOWLEDGEMENT

We are grateful to Dr. Stewart Mckie for his help in data collection.

REFERENCES

1. Olsen KD. Tumors and surgery of the parapharyngeal space. *Laryngoscope* 1994;104:1-28.
2. Som PM, Curtin HD. Lesions of the parapharyngeal space. Role of MR imaging. *Otolaryngol Clin North Am* 1995;28:515-42.
3. Hoek AE, Mollink SM, Huff JS. Syncope: Risk stratification and clinical decision making. *Emerg Med Pract* 2014;16:1-22; quiz 22-3.
4. Unger JM, Chintapalli KN. Computed tomography of the parapharyngeal space. *J Comput Assist Tomogr* 1983;7:605-9.
5. Chung CH, Gillison ML. Human papillomavirus in head and neck cancer: Its role in pathogenesis and clinical implications. *Clin Cancer Res* 2009;15:6758-62.
6. Riffat F, Dwivedi RC, Palme C, Fish B, Jani P. A systematic review of 1143 parapharyngeal space tumors reported over 20 years. *Oral Oncol* 2014;50:421-30.
7. Minkara A, Dhanda-Patil R, Patil Y. Syncope caused by a pleomorphic adenoma: Case report and literature review. *Ear Nose Throat J* 2018;97:E23-6.
8. Toorop RJ, Scheltinga MR, Moll FL, Bleys RL. Anatomy of the carotid sinus nerve and surgical implications in carotid sinus syndrome. *J Vasc Surg* 2009;50:177-82.
9. McIntosh S, Lawson J, Kenny R. The clinical characteristics of vasodepressor and cardioinhibitory carotid sinus syndrome in the elderly. *Age Ageing* 1993;3:17.
10. Degirmenci E, Erdogan C, Aras D, Oğuzhanoglu A. Nasopharyngeal carcinoma presenting with horner syndrome and carotid-sinus syncope. *Neurologist* 2012;18:208-10.
11. Alhilali L, Reynolds AR, Fakhran S. Osteoradionecrosis after radiation therapy for head and neck cancer: Differentiation from recurrent disease with CT and PET/CT imaging. *AJNR Am J Neuroradiol* 2014;35:1405-11.
12. Bashar K, McHugh S, Burke P, Kavanagh E. Cerebral hypoperfusion secondary to radiation arteritis presenting with recurrent syncope. *BMJ Case Rep* 2014;2014:bcr2013203387.
13. Prefasi D, Martínez-Sánchez P, Fuentes B, Díez-Tejedor E. Bilateral carotid occlusion and progressive stenosis of vertebral arteries after radiotherapy in a young patient. *Neurologia* 2012;27:122-4.
14. Zhang S, Wei C, Zhang M, Su M, He S, He Y. Syncope and hypotension associated with carotid sinus hypersensitivity in a patient with nasopharyngeal carcinoma: A case report. *Medicine (Baltimore)* 2018;97:e12335.

How to cite this article: Agilinko J, Ganesh V, Ahmeidat A, Ram B, Shakeel M. A Sinister Cause for Recurrent Syncope: Metastatic Parapharyngeal Space Tumor. *Asclepius Med Case Rep* 2020;3(1):1-4.