

New Biliary Malformation: Bile Lake in the Gallbladder Bed Formed by Discharge from the Right Bile Duct

Francisco Javier Pérez Lara¹, José Manuel Hernández González²,
Francisco Javier Moya Donoso², Tatiana Prieto-Puga Arjona²,
Juan Doblaz Fernández², María Pitarch Martínez²

¹Department of Surgery, Chief of Digestive Surgery, Antequera Hospital, Málaga, Spain, ²Department of Surgery, Digestive Surgeon, Service of Digestive Surgery, Antequera Hospital, Málaga, Spain

ABSTRACT

The anatomy of the bile duct is frequently subject to alterations, to which digestive surgeons should be attentive during a gallbladder or bile duct intervention. We present an unusual case of a malformation which, to the best of our knowledge, has not been described previously. In this case, two ducts emerged from the right bile duct, discharging into a bile lake within the gallbladder bed. The patient was an 80-year-old male who had undergone cholecystectomy after an episode of pancreatitis. During the procedure (and confirmed by cholangio-Nuclear Magnetic Resonance), a bile lake was observed within the gallbladder bed, which was connected to the fundus of the gallbladder. The situation was resolved by carefully dissecting the gallbladder bed and subsequently clipping and resecting the communicating duct. In performing surgical interventions affecting the bile ducts, it is important to be aware of the anatomical variants that may be encountered. We present a clinical case which, to the best of our knowledge, has not been described previously. In our opinion, the possible existence this kind of anatomical variant should be taken into account, to avoid potentially severe injury.

Key words: Biliary malformation, bile lake, gallbladder

INTRODUCTION

The anatomy of the bile ducts follows the segmentation of the portal system in the liver. However, only half present “normal anatomy.” It has been suggested that there exist anatomical variants of normality up to 40% of cases.^[1,2] The surgeon should be aware of these possible variations in the anatomy of the gallbladder, the bile ducts, and their tributary arteries.^[3] This question has been highlighted with the advent of laparoscopic gallbladder surgery, interventions for hepato-biliary tumors, and liver transplants. Ignorance of such an anatomic variation may lead to significant injury being caused during surgery, such as inadvertent ductal ligation, biliary leaks, or ductal stenosis.^[4,5]

We present a case of bile duct abnormality. To the best of our knowledge, these circumstances have not been described previously in the medical literature.

CASE HISTORY

A 80-year-old male patient with a history of Stage III chronic obstructive pulmonary disease, who presented with acute biliary pancreatitis (Balthazar Grade IV), which was progressing favorably with conservative treatment. Five months later, after complete clinical and radiological recovery, a cholecystectomy was performed. Before the intervention, a cholangio resonance was performed. There was no choledocholithiasis, but the image revealed the emergence of two anomalous ducts from

Address for correspondence:

Francisco Javier Pérez Lara, Hospital de Antequera, Secretaría de Cirugía (3º Planta), Avenida Poeta Muñoz Rojas s/n, Antequera, Málaga. 29200, Spain

© 2020 The Author(s). This open access article is distributed under a Creative Commons Attribution (CC-BY) 4.0 license.

the right hepatic duct, leading to the gallbladder bed, and creating a bile lake along their length [Figure 1].

During the intervention, after clipping and resecting the duct and the cystic artery, the gallbladder was carefully separated from the liver bed, confirming the presence of abnormal ducts [Figure 2], which formed a biliary cavity occupying the entire gallbladder bed [Figure 3]. We observed (although this had not been apparent in the cholangio- Nuclear Magnetic Resonance [NMR]) that this cavity provided a Luschka duct to the upper area, which, in turn, communicated with the fundus of the gallbladder. This duct was clipped and resected to complete the cholecystectomy [Figure 4].

The rest of the intervention and the post-operative period were uneventful, and the patient was discharged on the second post-operative day.

DISCUSSION

The anatomy of the bile duct is subject to frequent alterations. Knowledge of embryological development and the normal anatomy of the biliary tree are fundamental to understanding and identifying this group of anomalies. The incidence of accessory bile ducts ranges from 1 to 30%.^[6-11] This anomaly is associated with the risk of inadvertent injury to a tributary channel.^[12] These are relatively unusual and difficult to recognize due to their unusual position and narrow caliber.^[9]

In approximately 5% of cases, a long cystic duct is formed, which merges abnormally with the right hepatic duct. This extensive dissection of the distal portion of the duct sometimes provokes the devascularization of part of the right hepatic duct, and subsequently ischemia, fibrosis, and stenosis at the junction of the cystic duct with the right hepatic duct.^[13]

If the cystic duct is very short (<5 mm long), which occurs in up to 2% of cases, this can lead to the hepatic duct being damaged during ligation or resection of the cystic duct. Moreover, the angulation produced by traction when the clip is inserted may dilate the junction of the hepatic ducts.^[14]

Other anomalies, such as the Phrygian cap deformity, which is the most common congenital anomaly of the gallbladder, have been observed in 2-6% of cases,^[15] but are not usually of pathological importance.^[16]

However, the incidence of the malformation, we describe is unknown. It may have been an isolated case, or more cases may have occurred, unreported. What is clear is that this issue is important and should be taken into account when a cholecystectomy must be performed, since an injury to this biliary lake could occur during detachment of the gallbladder, hampering its closure and provoking problems such as biliary peritonitis and leakage in the post-operative period.

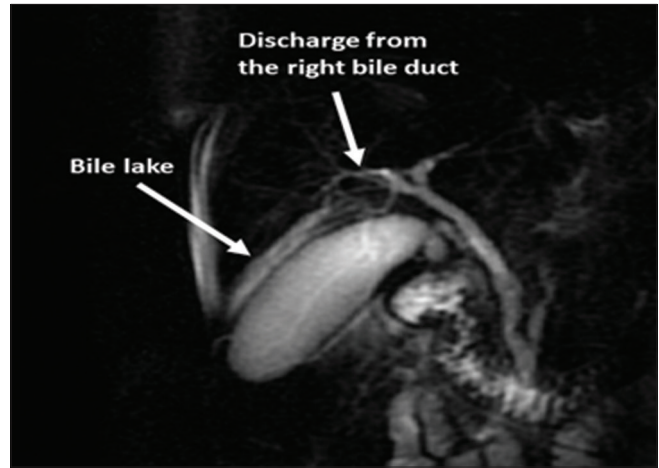


Figure 1: Cholangio resonance: Bile lake in the gallbladder bed formed by discharge from the right bile duct

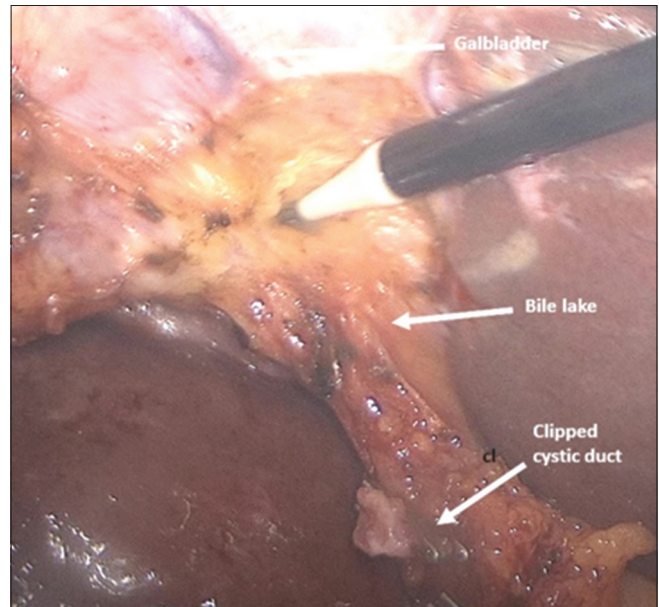


Figure 2: Gallbladder is being carefully separated from the liver bed, confirming the presence of abnormal ducts

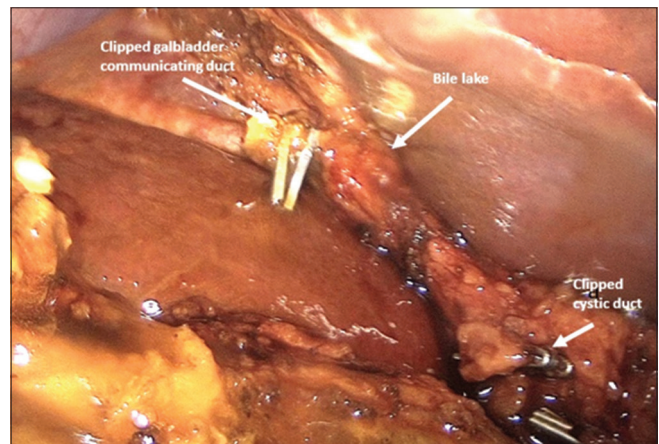


Figure 3: Biliary cavity occupying the entire gallbladder bed

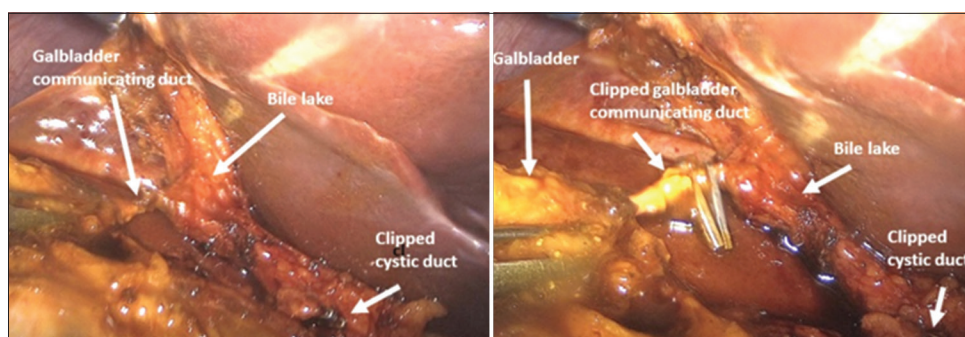


Figure 4: Biliary cavity provided a channel to the upper area, which, in turn, communicated with the fundus of the gallbladder. It was clipped and resected

Therefore, it is important for the surgeon to be aware of these anatomic variants before performing laparoscopic cholecystectomy. Nevertheless, pre-operative diagnosis in this respect under routine examination conditions is often difficult and/or exceptional,^[17] and so when this sort of problem arises during laparoscopic surgery it tends to be unexpected.

On the other hand, recent advances have enabled radiological evaluations such as magnetic resonance, cholangio resonance, and multi-slice helical computed tomography to improve the image quality obtained, thus facilitating recognition of these structures.^[5] In our case, the anomaly was detected by cholangio-NMR and this information provided a route map during the surgical intervention.

In view of these considerations, the surgeon should be alert to the possible presence of such abnormalities during laparoscopic cholecystectomy, to prevent inadvertent duct injury, stenosis, and bleeding.

To the best of our knowledge, no anatomical malformation such as the one, we describe has been reported previously. The present information is important because ignorance of this possibility may lead to severe, unexpected consequences during the separation of the gallbladder bed. We do not know if it is an isolated case or if others occur, although rarely. For this reason, we are currently studying whether similar cases have been detected by cholangio resonance, to determine the real incidence of this type of malformation.

AUTHORS CONTRIBUTION

FJ Pérez Lara: made a substantial contribution to the concept and design, drafted the article or revised it critically for important intellectual content, approved the version to be published. JM Hernández González: Approved the version to be published. F.J. Moya Donoso: Approved the version to be published. T. Prieto-Puga: Approved the version to be published. J. Doblas Fernández: Approved the

version to be published. M. Pitarch Martínez: Approved the version to be published.

REFERENCES

1. Griffin N, Charles-Edwards G, Grant LA. Magnetic resonance cholangiopancreatography: The ABC of MRCP. *Insights Imaging* 2011;3:11-21.
2. Cachoeira E, Rivas A, Gabrielli C. Anatomic variations of extrahepatic bile ducts and evaluation of the length of ducts composing the cystohepatic triangle. *Int J Morphol* 2012;30:279-83.
3. Mortelé KJ, Ros PR. Anatomic variants of the biliary tree. *Am J Roentgenol* 2001;177:389-94.
4. De Filippo M, Calabrese M, Quinto S, Rastelli A, Bertellini A, Martora R, *et al.* Congenital anomalies and variations of the bile and pancreatic ducts: Magnetic resonance cholangiopancreatography findings, epidemiology and clinical significance. *Radiol Med* 2008;113:841-59.
5. Nagral S. Anatomyrelevant to cholecystectomy. *J Minimal Access Surg* 2005;1:538.
6. Gibney RG, Nichols DM, Osborne JC, Fache JS, Burhenne HJ. Intrahepatic duct, a new biliary anomaly. *Gastrointest Radiol* 1987;12:134-6.
7. Hamlin JA. Biliary ductal anomalies. In: Berci G, Hamlin JA, editors. *Operative Biliary Radiology*. Baltimore: Williams and Wilkins; 1981. p. 109-35.
8. Hermann RE. A plea for a safer technique of cholecystectomy. *Surgery* 1976;79:609-11.
9. Pollock EL, Tabrisky J. The aberrant divisional bile duct: A surgical hazard. *Surgery* 1973;73:234-9.
10. Hayes MA, Goldenberg IS, Bishop CC. The development albasis for bile duct anomalies. *Surg Gynecol Obst* 1958;107:447-56.
11. Healey JE Jr., Schroy PC. Anatomy of the biliary ducts with in the human liver: Analysis of the prevailing pattern of branchings and the major variations of the biliary ducts. *AMA Arch Surg* 1953;66:599-616.
12. Lichtenstein ME, Nicosia AJ. The clinical significance of accessory hepato biliary duct. *Ann Surg* 1970;141:120-4.
13. Russell RO, Williams NS, Bulstrode CJ. *Bailey and Love's: Short Practice of Surgery*. 23rd ed., Vol. 2. New York: Arnold; 2000. p. 965-86.
14. Adkins RB, Champan WC, Reddy VS. Embryology, Anatomy and surgical applications of the extrahepatic biliary system.

- Surg Clin North Am 2000;8:363-79.
15. Russel RC. The gall bladder and bileducts. In: Russell RC, Williams NS, Bulstrode CJ, editors. Baily and Love Short Practice of Surgery. 24th ed. New York: Arnold International Students; 2004. p. 1094-113.
 16. Lamah M, Karanjia ND, Dickson GH. Anatomical variations of extrahepatic biliary tree: Review of the world literature. Clin Anat 2001;14:167-72.
 17. Mortele KJ, Rocha TC, Streeter JL, Taylor AJ. Multimodality

imaging of pancreatic and biliary congenital anomalies. Radiographics 2006;26:715-31.

How to cite this article: Pérez Lara FJ, Hernández González JM, Moya Donoso FJ, Prieto-Puga Arjona T, Doblás Fernández J, Pitarich Martínez M. New Biliary Malformation: Bile Lake in the Gallbladder Bed Formed by Discharge from the Right Bile Duct. Clin J Surg 2020;3(2):1-4.