

# Feminizing Adrenocortical Tumor: Report of a Case

Elisa Guidoni, Federica Lotti, Ursula Geronzi, Salvatore Grosso, Giovanna Municchi

*Department of Molecular Medicine and Development, Section of Pediatrics, University of Siena, Siena, Italy*

## ABSTRACT

The annual worldwide incidence of childhood adrenocortical tumors (ACTs) is 0.3–0.38 per million children. Only 1–2% of them are feminizing ACTs. We present a case of feminizing ACT. The boy was referred at the chronological age of 7.5 years for bilateral gynecomastia Tanner stage II. Testes were prepubertal. Serum investigations showed elevated 17-beta-estradiol: 56.6 pg/ml (prepubertal values <15 pg/ml). Abdominal ultrasound revealed a mass in the adrenal gland. A transabdominal adrenalectomy was performed. Histological examination demonstrated an adrenal cortical adenoma with low malignant potential. 2 months after surgery gynecomastia regressed and serum 17-beta-estrogen levels normalized. Prepubertal gynecomastia is a rare disorder that could be associated with severe underlying diseases. Since prepubertal gynecomastia could represent a clinical sign of adrenal or testicular tumors, a thorough examination is mandatory. Since these tumors may be aggressive and unpredictable, early diagnosis and surgical excision are essential.

**Key words:** Adrenal adenoma, feminizing tumor, gynecomastia, pediatric adrenocortical tumor

## BACKGROUND

Adrenocortical tumors (ACTs) are rare in childhood, with an estimated annual incidence of 0.3–0.38 cases per million below the age of 15 years, representing about 0.2% of all pediatric malignancies.<sup>[1]</sup>

The incidence varies across geographic areas and is considerably high in the south part of Brazil.<sup>[2,3]</sup> ACTs are more common in girls (female/male ratio 2:1) being characterized by two peaks of incidence, the first under 3 years of age and the second during adolescence.<sup>[4-6]</sup> The first peak is caused by tumors arising from the fetal (embryonal) adrenal gland and the second one is due to those arising from the cortex of the definitive adrenal gland.<sup>[6]</sup>

Most ACTs are functional and clinical manifestation depends on the specific hormone produced by the tumor. Virilization, isolated or in combination with hypercortisolism, is the most common presentation (80%), followed by Cushing's syndrome and hyperaldosteronism.<sup>[7,8]</sup> Feminization is rare.<sup>[9]</sup>

Clinical presentation may not reflect the abnormal hormone secretion in all patients. Therefore, a complete evaluation of hormone profile is essential to determine an excess of hormones as tumor markers. Moreover, during follow-up, hormones tumor markers can be used as indicators of recurrence. Moreover, a complete hormonal evaluation is essential to evaluate patients at risk of adrenal suppression after surgery.<sup>[10]</sup> Tumor histology is crucial for the diagnosis and the appropriate treatment and follow-up.<sup>[11]</sup>

Many studies have demonstrated a strong association between ACTs and constitutional p53 tumor suppression gene mutations; therefore, genetic analysis for p53 status should be considered in these patients.<sup>[12-16]</sup> The p53 mutations are more common in malignant neoplasms and represent a sentinel event of Li-Fraumeni syndrome.<sup>[12,13,17,18]</sup>

Adrenalectomy is the gold standard for non-metastatic ACTs treatment. Chemotherapy is used in addition to surgery in the advanced stages and includes cisplatin, etoposide, doxorubicine, and mitotane, which is an insecticide derivative that causes necrosis of adrenocortical cells and inhibits

### Address for correspondence:

Elisa Guidoni, Department of Molecular Medicine and Development, Section of Pediatrics, University of Siena, Siena, Italy. E-mail: elisaguidoni9@gmail.com

© 2018 The Author(s). This open access article is distributed under a Creative Commons Attribution (CC-BY) 4.0 license.

corticosteroids biosynthesis.<sup>[19-23]</sup> At present, there are no well-controlled studies to compare the benefit of different drugs as first-line therapy or as adjuvant therapy.<sup>[9]</sup>

Pediatric ACTs have a better prognosis than adults' tumors, in particular in patients younger than 4 years.<sup>[6,24]</sup>

There are no clinical and hormonal features that can differentiate malignant form. At present tumor size or weight represents the only reliable prognostic factor.<sup>[6,13,25]</sup>

We present a case of a 7-year-old boy affected by a feminizing ACT.

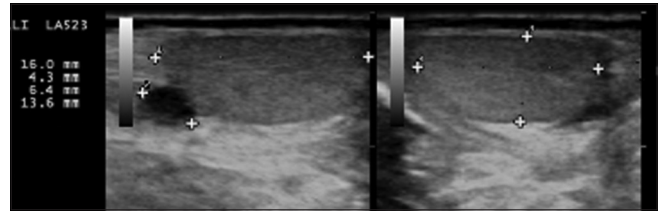
## CASE REPORT

The boy was referred to the Pediatric Endocrinology Outpatient Clinic of the University of Siena at the chronological age of 7.5 years with bilateral gynecomastia, which had appeared 6 months previously. No significant family and medical history were present. On auxological examination, height was 139 cm (>97<sup>o</sup> percentile), target height 75<sup>o</sup> percentile, weight was 27,500 kg (50<sup>o</sup>–75<sup>o</sup> percentile), and bilateral gynecomastia Tanner Stage II was present. Testes were prepubertal, of normal consistency, and stretched penile length was appropriate for age. No pubic or axillary hair was present. Cardiorespiratory and abdominal examination revealed no abnormalities, heart rate was 90/min, and blood pressure was 95/60 mmHg. Baseline investigations showed normal blood count, electrolytes, and liver and renal function. Serum free thyroxine, thyroid stimulating hormone, follicle stimulating hormone, luteinizing hormone, Prolactin, Cortisol (8:00 AM plasma levels), and Testosterone were within prepubertal limits. Serum levels of dehydroepiandrosterone sulfate (DHEAS) were normal 221 µg/ml (ref range 120–520). Serum levels of Androstenedione were near to the upper limit: 3,08 ng/ml (ref range 0.4-3,1). Serum 17-beta-estradiol was elevated: 56.6 pg/ml (prepubertal values <20). Ultrasound of the tests revealed no abnormalities. Abdominal ultrasound demonstrated a mass in the right adrenal gland measuring 2.6 cm in diameter [Figure 1].

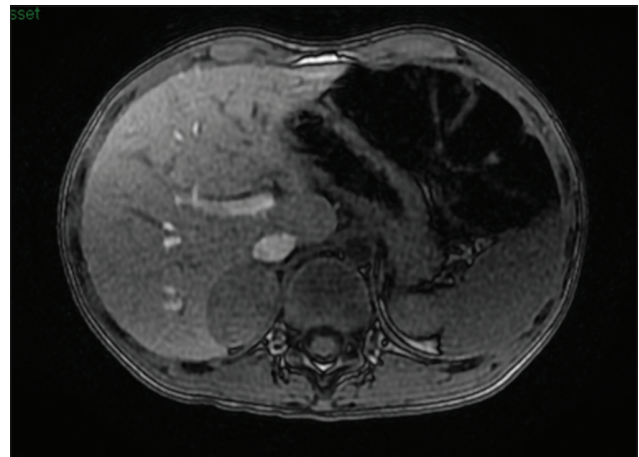
Abdominal magnetic resonance (MR) confirmed the mass, with characteristics compatible with adrenal adenoma [Figures 2 and 3].

The diagnosis was consistent with adrenocortical adenoma with low malignant potential.

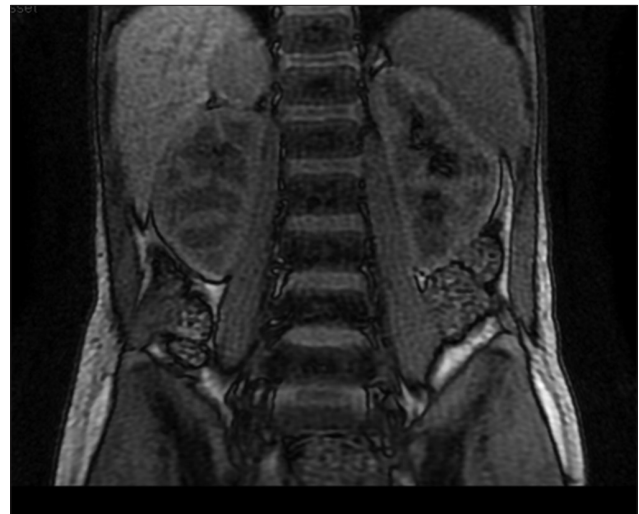
The planned follow-up includes abdominal ultrasound, every 4 months for the 1<sup>st</sup> year and then every 6 months up to 3 years after surgery, and serum measurement of 17-beta-estradiol, DHEAS, Androstenedione, Cortisol, and Testosterone every 3 months during the 1<sup>st</sup> year, and then every 6 months up to 3 years after surgery.



**Figure 1:** Abdominal ultrasound demonstrated a mass in the right adrenal gland measuring 2.6 cm in diameter



**Figure 2:** Abdominal magnetic resonance transverse section. The arrow indicates the mass in the right adrenal gland with characteristics compatible with adrenal adenoma



**Figure 3:** Abdominal magnetic resonance coronal section. The arrow indicates the mass in the right adrenal gland with characteristics compatible with adrenal adenoma

2 months after surgery gynecomastia completely regressed and serum 17-beta-estradiol, DHEAS and Androstenedione levels normalized.

At the last evaluation, 12 months after surgery, the patient is well; 17-beta-estradiol levels are <20 pg/ml, and abdominal ultrasound is negative.

## CONCLUSIONS

ACT in children represent a rare occurrence, especially those secreting predominantly estrogen. Estrogens' overproduction results from an increase in aromatase activity in the adrenal tissue.<sup>[26]</sup>

Since Wilkins' first description in 1948, there have been only 22 cases of feminizing ACTs in childhood described in the literature.<sup>[26-49]</sup> To analyze prevalence, sex distribution, age at diagnosis, and clinical presentation of feminizing ACTs we performed a review of all the articles published from 1948 to 2015. We performed a PubMed search using the following search strings: Pediatric ACTs and feminizing adrenal tumors.

According to our review, although ACTs are more common in girls, feminizing ACTs occurred more frequent in males (male/female ratio 2:1). Feminizing ACTs are more common  $\leq 7$  years of age (90.5%), with a mean age at diagnosis of 5.4 years with a range from 0.3 to 14 years.

The clinical presentation of feminizing ACTs is characterized by gynecomastia in males and pseudo precocious puberty in girls, in one case clinical findings commonly associated with ACTs were absent, a female infant presented left abdominal mass, weight loss, irritability, and increasing abdominal girth.<sup>[40]</sup> A palpable mass is rare in children.<sup>[9,40,43]</sup>

Stage classification, histopathologic criteria, and prognosis were based on ACTs in adults. The prognosis of feminizing ACTs in adults is worse with respect to ACTs in childhood, due to the fact that the diagnosis is carried out earlier before puberty. ACTs in childhood have a tendency to appear in prepubertal ages, therefore excess adrenal hormones can easily be noticed before puberty.<sup>[9,10,50,51]</sup> However, the prognosis changes dramatically with the progression to metastatic disease. Long-term survival is expected in 90% of patients with small, completely resectable neoplasms, whereas in patients with distant metastases 5-year overall survival rate decreases to 10%. Therefore, an early diagnosis is essential, but often it is delayed.<sup>[6]</sup>

A report from the International Pediatric Adrenocortical Tumor Registry demonstrated that the median interval between the first signs or symptoms of ACTs and the diagnosis was 5 months with a range from a few days to 8 years.<sup>[6]</sup> Furthermore, in our case, the interval was more than 6 months from the onset of gynecomastia to the detection of the tumor.

The reasons for this delay are probably multifactorial. First, small neoplasms can produce slight clinical manifestations. Second, these children do not appear sick, except for their endocrine manifestations (accelerated growth, pubertal development, and advanced bone age).<sup>[6]</sup> Third, the clinical

manifestations caused by an excess of sex hormones due to ACT can easily be masked during and after puberty.<sup>[10]</sup> Finally, the delay could be due to an atypical presentation.<sup>[52]</sup>

History, physical examination, complete hormonal evaluation, and targeted imaging (abdominal and testes ultrasonography) are all useful tools to achieve early diagnosis.

Unlike pubertal gynecomastia, which is a physiologic phenomenon occurring in about 60% of adolescents, prepubertal gynecomastia is uncommon but could represent a clinical sign of a major underlying condition, such as adrenal or testicular tumors.

These tumors could be aggressive and unpredictable; therefore, thorough clinical and laboratory examination are essential to make an early diagnosis and to perform a surgical intervention and appropriate long-term follow-up.

## REFERENCES

1. Chudler RM, Kay R. Adrenocortical carcinoma in children. *Urol Clin North Am* 1989;16:469-79.
2. Sandrini R, Ribeiro RC, DeLacerda L. Childhood adrenocortical tumors. *J Clin Endocrinol Metab* 1997;82:2027-31.
3. Dehner LP, Hill DA. Adrenal cortical neoplasms in children: Why so many carcinomas and yet so many survivors? *Pediatr Dev Pathol* 2009;12:284-91.
4. Ribeiro RC, Neto RS, Shell MJ, Lacerda L, Sambaio, Cat I. Adrenocortical carcinoma in children: A study of 40 cases. *J Clin Oncol* 1990;8:67-74.
5. Wieneke JA, Thompson LD, Heffess CS. Adrenal cortical neoplasms in the pediatric population: A clinicopathologic and immunophenotypic analysis of 83 patients. *Am J Surg Pathol* 2003;27:867-81.
6. Michalkiewicz E, Sandrini R, Figueiredo B, Miranda EC, Caran E, Oliveira-Filho AG, *et al.* Clinical and outcome characteristics of children with adrenocortical tumors: A report from the international pediatric adrenocortical tumor registry. *J Clin Oncol* 2004;22:838-45.
7. Ribeiro RC, Figueiredo B. Childhood adrenocortical tumors. *Eur J Cancer* 2004;40:1117-26.
8. Sutter JA, Grimberg A. Adrenocortical tumors and hyperplasias in childhood – etiology, genetics, clinical presentation and therapy. *Pediatr Endocrinol Rev* 2006;4:32-9.
9. Chentli F, Bekkaye I, Azzoug S. Feminizing adrenocortical tumors: Literature review. *Indian J Endocrinol Metab* 2015;19:332-9.
10. Gönç EN, Özön ZA, Cakır MD, Alikışıoğlu A, Kandemir N. Need for comprehensive hormonal workup in the management of adrenocortical tumors in children. *J Clin Res Pediatr Endocrinol* 2014;6:68-73.
11. Xu X, Sergi C. Pediatric adrenal cortical carcinomas: Histopathological criteria and clinical trials. A systematic review. *Contemp Clin Trials* 2016;50:37-44.
12. Wasserman JD, Novokmet A, Eichler-Jonsson C, Ribeiro RC, Rodriguez-Galindo C, Zambetti GP, *et al.* Prevalence and functional consequence of TP53 mutations in pediatric

- adrenocortical carcinoma: A children's oncology group study. *J Clin Oncol* 2015;33:602-9.
13. Dall'Igna P, Virgone C, De Salvo GL, Bertorelle R, Indolfi P, De Paoli A, *et al.* Adrenocortical tumors in Italian children: Analysis of clinical characteristics and P53 status. Data from the national registries. *J Pediatr Surg* 2014;49:1367-71.
  14. Custódio G, Komechen H, Figueiredo FR, Fachin ND, Pianovski MA, Figueiredo BC, *et al.* Molecular epidemiology of adrenocortical tumors in southern Brazil. *Mol Cell Endocrinol* 2012;351:44-51.
  15. Wasserman JD, Zambetti GP, Malkin D. Towards an understanding of the role of p53 in adrenocortical carcinogenesis. *Mol Cell Endocrinol* 2012;351:101-10.
  16. Herbet M, Feige JJ, Thomas M. Insights into the role of genetics alterations in the adrenocortical tumorigenesis. *Mol Cell Endocrinol* 2009;300:169-74.
  17. Ribeiro RC, Pinto EM, Zambetti GP, Rodriguez-Galindo C. The international pediatric adrenocortical tumor registry initiative: Contributions to clinical, biological, and treatment advances in pediatric adrenocortical tumors. *Mol Cell Endocrinol* 2012;351:37-43.
  18. Fiszer-Maliszewska L, Kazanowska B, Padzik J, Regional Blood Transfusion Center. P53 tetramerization domain mutations: Germline R342X and R342P, and somatic R337G identified in pediatric patients with Li-Fraumeni syndrome and a child with adrenocortical carcinoma. *Fam Cancer* 2009;8:541-6.
  19. Mihai R. Diagnosis, treatment and outcome of adrenocortical cancer. *Br J Surg* 2015;102:291-306.
  20. Terzolo M, Daffara F, Ardito A, Zaggia B, Basile V, Ferrari L, *et al.* Management of adrenal cancer: A 2013 update. *J Endocrinol Invest* 2014;37:207-17.
  21. Veytsman I, Nieman L, Fojo T. Management of endocrine manifestations and the use of mitotane as a chemotherapeutic agent for adrenocortical carcinoma. *J Clin Oncol* 2009;27:4619-29.
  22. Kirschner LS. Emerging treatment strategies for adrenocortical carcinoma: A new hope. *J Clin Endocrinol Metab* 2006;91:14-21.
  23. Williamson SK, Lew D, Miller GJ, Balcerzak SP, Baker LH, Crawford ED, *et al.* Phase II evaluation of cisplatin and etoposide followed by mitotane at disease progression in patients with locally advanced or metastatic adrenocortical carcinoma: A Southwest oncology group study. *Cancer* 2000;88:1159-65.
  24. Kerkhofs TM, Ettaieb MH, Verhoeven RH, Kaspers GJ, Tissing WJ, Loeffen J, *et al.* Adrenocortical carcinoma in children: First population-based clinicopathological study with long-term follow-up. *Oncol Rep* 2014;32:2836-44.
  25. Klein JD, Turner CG, Gray FL, Yu DC, Kozakewich HP, Perez-Atayde AR, *et al.* Adrenal cortical tumors in children: Factors associated with poor outcome. *J Pediatr Surg* 2011;46:1201-7.
  26. Moreno S, Guillermo M, Decoulx M, Dewailly D, Bresson R, Proye Ch, *et al.* Feminizing adrenocortical carcinomas in male adults. A dire prognosis. Three cases in a series of 801 adrenalectomies and review of the literature. *Ann Endocrinol (Paris)* 2006;67:32-8.
  27. Sindgikar SP, Joshi SS, Shenoy V. Feminizing adrenal tumor: A rare presentation. *Iran J Pediatr* 2014;24:225-6.
  28. Bouyahia O, Gharsallah L, Ouederni M, Boukthir S, Mrad SM, El Gharbi AS. Feminizing adrenocortical adenoma in a 5 year-old girl. *J Pediatr Endocrinol Metab* 2009;22:79-84.
  29. Hsiao HP, Chao MC, Lin CY, Chen HL, Chiou SS, Chen BH, *et al.* Feminizing adrenocortical adenoma presenting as heterosexual precocious puberty: Report of one case. *Acta Paediatr Taiwan* 2005;46:97-100.
  30. Phornphutkul C, Okubo T, Wu K, Harel Z, Tracy TF Jr., Pinar H, *et al.* Aromatase p450 expression in a feminizing adrenal adenoma presenting as isosexual precocious puberty. *J Clin Endocrinol Metab* 2001;86:649-52.
  31. Watanabe T, Yasuda T, Noda H, Wada K, Kazukawa I, Someya T, *et al.* Estrogen secreting adrenal adenocarcinoma in an 18-month-old boy: Aromatase activity, protein expression, mRNA and utilization of gonadal type promoter. *Endocr J* 2000;47:723-30.
  32. Ghazi AA, Mofid D, Rahimi F, Marandi H, Nasri H, Afghah S, *et al.* Oestrogen and cortisol producing adrenal tumour. *Arch Dis Child* 1994;71:358-9.
  33. Qin WB. Feminizing adrenocortical tumor. *Zhonghua Wai Ke Za Zhi* 1991;29:635-6, 654.
  34. Bass J, Sochett E. Prepubertal gynecomastia: A cause for concern. *Can Fam Physician* 1991;37:995-1026.
  35. Galifer RB, Couture A, Dyon JF, Chappuis JP, Valla JS, Chavier Y, *et al.* Solid tumors of the adrenal gland in children (excluding neuroblastomas). A study of a series of 18 cases. *Chir Pediatr* 1989;30:209-14.
  36. Comite F, Schiebinger RJ, Albertson BD, Cassorla FG, Vander Ven K, Cullen TF, *et al.* Isosexual precocious pseudopuberty secondary to a feminizing adrenal tumor. *J Clin Endocrinol Metab* 1984;58:435-40.
  37. Itami RM, Amundson GM, Kaplan SA, Lippe BM. Prepubertal gynecomastia caused by an adrenal tumor. Diagnostic value of ultrasonography. *Am J Dis Child* 1982;136:584-6.
  38. Drop SL, Bruining GJ, Visser HK, Sippell WG. Prolonged galactorrhoea in a 6-year-old girl with isosexual precocious puberty due to a feminizing adrenal tumour. *Clin Endocrinol (Oxf)* 1981;15:37-43.
  39. Wohltmann H, Mathur RS, Williamson HO. Sexual precocity in a female infant due to feminizing adrenal carcinoma. *J Clin Endocrinol Metab* 1980;50:186-9.
  40. Visconti EB, Peters RW, Cangir A, Zorn GL Jr., Fisher S. Unusual case of adrenal cortical carcinoma in a female infant. *Arch Dis Child* 1978;53:342-4.
  41. Bhattay E, Bonnici F. Pure oestrogen-secreting feminizing adrenocortical adenoma. *Arch Dis Child* 1977;52:241-3.
  42. Howard CP, Takahashi H, Hayles AB. Feminizing adrenal adenoma in a boy. Case report and literature review. *Mayo Clin Proc* 1977;52:354-7.
  43. Leditschke JF, Arden F. Feminizing adrenal adenoma in a five year old boy. *Aust Paediatr J* 1974;10:217-21.
  44. Banich FE, Fox PF. Feminizing tumor of the adrenal gland in a five-year-old female. *Proc Inst Med Chic* 1970;28:82.
  45. Bacon GE, Lowrey GH. Feminizing adrenal tumor in a six-year-old boy. *J Clin Endocrinol Metab* 1965;25(10):1403-6.
  46. Mosier HD, Goodwin WE. Feminizing adrenal adenoma in a 7-year-old boy. *Pediatrics* 1961;27:1016-21.
  47. Snaith AH. A case of feminizing adrenal tumor in a girl. *J Clin Endocrinol Metab* 1958;18:318-22.
  48. Fontaine R, Sacrez R, Klein M, Frank P, Lausecker C, Stoll G, *et al.* Precocious puberty and development of breast in a boy in

- adrenal tumor. Arch Fr Pediatr 1954;11:417-20.
49. Wilkins L. A feminizing adrenal tumor causing gynecomastia in a boy of 5 years contrasted with a virilizing tumor in a 5 year old girl: Classification of 70 cases of adrenal tumor in children according to their hormonal manifestations and review of 11 cases of feminizing adrenal tumor in adults. Clin Endoc 1948;8:111-32.
50. Marques-Pereira R, DeLacerda L, Lacerda HM, Michalkiewickz E, Sandrini F, Sandrini R. Childhood adrenocortical tumors: A review. Hered Cancer Clin Pract 2006;4:81-9.
51. Rodriguez-Galindo C, Figueiredo BC, Zambetti GP, Ribeiro RC. Biology, clinical characteristics, and management of adrenocortical tumors in children. Pediatr Blood Cancer 2005;45:265-73.
52. Hagemann K, Zanolari Calderari M, Perren A, Cree I, Mullis PE, Flück CE, *et al.* Atypical presentation of a hormonally active adrenocortical tumor in an adolescent leading to delayed diagnosis. Hormones (Athens) 2011;10:317-25.

**How to cite this article:** Guidoni E, Lotti F, Geronzi U, Grosso S, Municchi G. Feminizing Adrenocortical Tumor: Report of a Case. Clin Res Diapetes Endocrinol 2018;1(1):1-5.