

Medical Treatment versus Radiofrequency Ablation for Patients with Trigeminal Neuralgia: A Prospective Clinical Study

Alaa Ali M. Elzohry^{1*}, Ashraf Mohamad Amin¹, Ali Taha Abdel-Wahab², Abeer A. M. Hassanin²

¹Department of Anesthesia, ICU and Pain Relief, South Egypt Cancer Institute, Assiut University, Assiut, Egypt,

²Department of Anesthesia and ICU, Faculty of Medicine, Minia University, Minia, Egypt

ABSTRACT

Background: Trigeminal neuralgia (TGN) is an extremely painful disorder which can be difficult to diagnose and treat. It presented with chronic pain or acute pain depending on the cause, which varies with the patients. The pain is unilateral in nature. It persists from few seconds to minutes it might extend to hours, this occurs in bouts lasting in weeks with remission of periods in years. TGN is associated with poor activity of daily living, suicidal attempts, and an overall decreased quality of life due to the unbearable pain. TGN is the most successfully treated neuropathic pain both medically and surgically. **Aim of the Work:** This study aimed to compare the medical treatment regimen versus interventional radiofrequency (RF) ablation in patients with TGN. **Patients and Methods:** Thirty patients of either sex aged between 18 and 60 years old who complaining of TGN enrolled in our study from March 2019 to October 2019. Patients were randomly allocated into two groups (15 patients each), to receive medical treatment Group M and RF ablation (Group RF). Pain was assessed over one using visual analog scale (VAS) plus time of the first analgesic request and overall analgesics consumption was recorded. Any concomitant complications were observed postoperatively. **Results:** As regard patient demographic data, we found that there were no significant changes between the two groups, as shown in Table 1 and Figure 1. There was a significant decrease in VAS pain scores in Group RF during the 1st day post-operative ($P = 0.001^*$) and analgesic consumption much more decreased in Group RF in comparison to Group M ($P = 0.001^*$), the difference between the two groups was significant ($P < 0.001$). **Conclusion:** Trigeminal neuralgia is a severe neuropathic type of pain affecting unilateral face and requires expert physician that treats it with different strategies with lifelong duration. RF is an effective, accurate, and precise procedure that provides efficient pain relief to TGN sufferers. RF is suggested in the elderly because it is more beneficial to them in terms of low morbidity and mortality.

Key words: Anticonvulsant, neuropathic pain, radiofrequency ablation, trigeminal neuralgia, visual analog scale score

INTRODUCTION

TGN can be presented with chronic pain or acute pain depending on the cause, which varies with the patients. Chronic pain differs greatly from acute pain in terms of the pain persistence and adaptation. Trigeminal neuralgia is associated with poor activity of daily living, suicidal attempts, and an overall decreased quality of life due to the unbearable pain.^[1,2]

Two clinical types of TGN are usually recognized, typical and atypical TGN. The hallmark of typical TGN is paroxysmal pain, which is lancinating in nature and occurs unilaterally in a trigeminal distribution. Paroxysmal pain is present in atypical TGN chronic pain, which persist beyond the duration of a typical paroxysm, in the same trigeminal distribution areas.^[3,4]

To get the maximum treatment efficacy from drugs, patient's compliance is needed. Improved patient compliance can

Address for correspondence:

Alaa Ali M. Elzohry, Department of Anesthesia, ICU and Pain Relief, South Egypt Cancer Institute, Assiut University, Assiut 71511, Arab Republic of Egypt. Phone: +20-88-2060010/+20-01007356462. E-mail: alaa.zohiry@hotmail.com

© 2019 The Author(s). This open access article is distributed under a Creative Commons Attribution (CC-BY) 4.0 license.

be achieved when the patient is explained about his illness completely by the doctor. The benefits and adverse effect of each drug should be explained to the patient. The doctor should have extracted the complete history from the patient. Maintaining pain diaries help to monitor the response to drugs.^[5,6]

Anticonvulsants are most commonly used for the pain management. Carbamazepine is considered as the first line of drug, in spite of its side effects. When this monotherapy fails, the second line of treatment is a combination of drugs such as carbamazepine with lamotrigine or with baclofen. Other drugs are phenytoin, lamotrigine, gabapentin, oxcarbazepine, and newer drugs like pregabalin.^[7-10]

Interventional techniques involving microvascular decompression (MVD), other posterior fossa surgery (partial sensory rhizotomy and internal neurolysis), Gamma Knife surgery, radiofrequency (RF) thermocoagulation, balloon compression (BC), and glycerol rhizolysis (GR) were sought up to January 2018.^[11-13]

RF treatment is defined as the delivery of short pulses of RF through a needle tip, thereby avoiding thermal lesions. This technique had been performed for various other conditions and has been shown to be effective and safe. There are contrasting opinions regarding the use of pulsed RF (PRF) treatment for TN, but in our opinion, one of the main reasons for this discrepancy is the insufficient PRF dose used in most studies.^[14,15]

The aim of this study was to compare the effects of medical treatment regimen versus interventional RF ablation in patients with TGN.

PATIENTS AND METHODS

This study was designed as a prospective randomized clinical trial and was conducted in Assiut University pain management unit, after obtaining local ethical committee approval and written consent from all included patients. Thirty patients from either sex aged between 18 and 60 years old who complaining of TGN enrolled in our study from March 2019 to October 2019.

TGN was diagnosed as follows

- Paroxysmal attacks of pain lasting from a fraction of a second to 2 min that affect one or more divisions of the trigeminal nerve
- Pain has at least one of the following characteristics intense, sharp, superficial, or stabbing precipitated from trigger areas or by trigger factors
- Attacks are similar in individual patients
- No neurological deficit is clinically evident
- Exclude any other central nervous system pathology or disorder.

Exclusion criteria were as follows: Allergy to local anesthetic solutions, patient refusal, patients who cannot be taught how to evaluate their own pain intensity, coagulopathy, and end organ failure.

All patients were taught how to evaluate their own pain intensity using the visual analog scale (VAS), scored from 0 to 10 (where 0 = no pain and 10 = worst pain imaginable).

All patients were randomly assigned into two groups (30 patients each) using opaque sealed envelopes containing computer-generated randomization schedule, the opaque sealed envelopes are sequentially numbered that were open before allocation of treatment plan.

- Group M ($n = 15$): Medical treatment was optimized in the form of carbamazepine and pregabalin
- Group RF ($n = 15$): RF ablation was done from the start then continues medical treatment.

Technique of RF ablation

The patient lies comfortably in a supine position with continuous hemodynamic monitoring and the head slightly extended. The C-arm is introduced in a posteroanterior fashion and rotated caudocranially to produce a submental view. The foramen ovale can be often already visualized with this view. The needle entry point is 2–3 cm from the corner of the mouth. An approach that worked well for us was to “bring the foramen ovale to the entry point” by manipulating the C-arm in a caudocranial orientation, which produced an excellent “tunnel view.”

The skin over the needle entry point is anesthetized with 1% lidocaine. Using an aseptic technique, the needle is directed toward the ipsilateral pupil. Up to 0.75 mg/kg of propofol is used to sedate the patient during the initial needle penetration into the foramen ovale. Once the needle enters the foramen ovale into Meckel’s cavity, the C-arm is then rotated laterally to ascertain the depth of penetration. The final position of the needle tip is just past the angle formed by the petrosal ridge of the temporal bone and the clivus.

The propofol sedation is discontinued, the patient is allowed to awaken, and sensory stimulation is carried out at 50 Hz. The definitive position of the electrode was verified by inducing paresthesia with sensory stimulation between 0.1 and 0.3 V in the infected painful area. Lesion RF applied for 2 min with cutoff needle tip temperature was set at 82°C.

In post-procedural period, all patients were observed for 1 month for the following parameters;

- VAS for pain measurement at regular intervals as primary outcome
- Secondary outcomes were
- Total doses of anticonvulsant that given the analgesic

regimen were adjusted to achieve a VAS score <3

- Any concomitant complications, if happened, as infections, hematoma, or paresthesia or side effects as nausea, vomiting, pruritus, or respiratory depression.

Statistical analysis

Data entry and analysis were done using the Statistical Package for the Social Sciences version 20[®]. Data were presented as number, percentage, and mean ± standard deviation. Chi-square test was used to compare between qualitative variables. Mann–Whitney U-test was used to compare quantitative variables between the studied groups. Wilcoxon signed-rank test was done to compare between each 2 times in the same group. *P*-value considered statistically significant when *P* < 0.05.

RESULTS

Our study included 15 patients who were planned for elective total knee replacement surgery. Patients were randomized into two groups:

- Group M (medical treatment)
- Group RF (lesion RF).

As regard patient demographic data and we found that there were no significant changes between the two groups, as shown in Table 1 and Figure 1. There was a significant decrease in VAS pain scores in Group RF during the 1st day post-operative (*P* = 0.001*) [Table 2 and Figure 2] and post-procedural analgesic consumption much more decreased in Group RF in comparison to Group M (*P* = 0.001*) [Table 3].

In the current study, no hematoma or excessive tissue trauma had been developed at the site of injection in Group RF; this result could probably due to the guidance of C-arm that enabled better visualization.

There were no significant differences between the two study groups in demographics regarding age, sex, weight, height,

body mass index, operative time, and blood loss (*P* > 0.05) [Table 1 and Figure 1].

DISCUSSION

Meaney *et al.* quantified the effect of carbamazepine on postural stability by petrography. It shows the composition equilibrium score scored significant reduction of postural stability with increase in the relation to the dose of carbamazepine. This was concluded that the rate of change of carbamazepine doses is an important determinant of cognitive and motor functions in the increasing dose phase.^[16]

Satoh *et al.* stated that carbamazepine is a safe drug comparatively and well tolerated with rare side effects like hematologic activity which began from rashes to life-threatening fumigant eruptions.^[17]

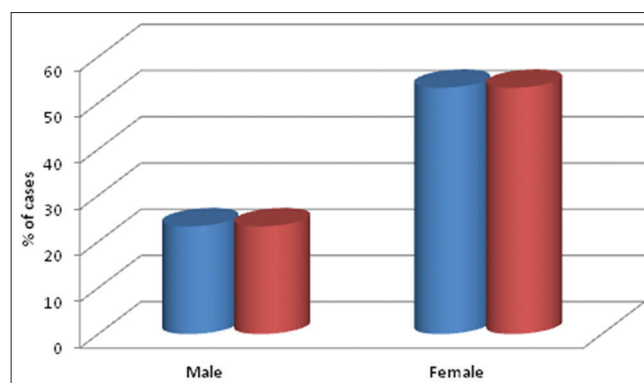


Figure 1: Gender distribution in the study groups

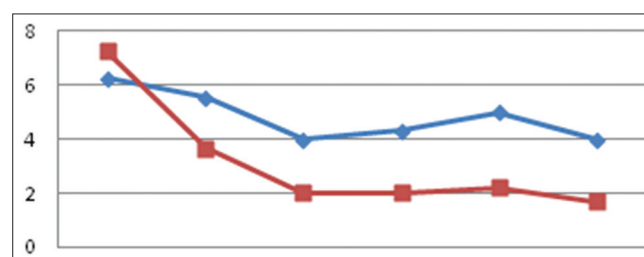


Figure 2: Visual analog scale score . VAS score in baseline – 1st day – 3rd day – 7th day – 15th day – 1 month. Red line is RF group blue line is M group

Table 1: Demographic data in the study group

Item	Group M (n=15)	Group RF (n=15)	<i>P</i> -value
Age	55.26±6.89	57.06±5.07	0.422 n.s
Sex			
Male	7 (23.3%)	7 (23.3%)	0.642 n.s
Female	8 (53.3%)	8 (53.3%)	
Weight	70.60±6.73	69.46±9.17	0.703 n.s
Height	166.07±6.43	166.8±7.26	0.772 n.s
BMI	25.59±1.89	24.85±1.46	0.242 n.s

BMI: Body mass index, n.s: Non-significant

Table 2: VAS score

VAS score	Group M	Group RF	<i>P</i> -value
VAS O	6.26	7.26	<0.8 n
VAS 1	5.53	3.67	0.876 n.s
VAS 3	4	2	0.371 n.s
VAS 7	4.3	2	0.318 n.s
VAS 15	5	2.2	0.232 n.s
VAS 30	4	1.7	0.318 n.s

VAS: Visual analog scale, n.s: Non-significant

Table 3: Comparison of analgesic among studied groups

Mean/SD	Group M (n=15)	Group RF (n=15)	P-value
Time of the first dose request	5.13±1.008	11.27±0.9	<0.001**
Total analgesic consumption mg/24 h	600.27±0.8	120.18±0.74	<0.001**

Data expressed as mean±SD. *P*<0.05 considered statistically significant. SD: Standard deviation

Ever all published series suggest a high level of initial success with MVD, most patients (87 ± 98%) experiencing immediate pain relief. Those series that present the proportion of patients with unrelieved or recurrent pain using Kaplan Knife show relatively similar results. At 2 years, the incidence of complete pain relief is 75 ± 80%. After 8 ± 10 years, this proportion has been reduced to 58 ± 64%, with a further 4 ± 12% suffering from minor recurrence only.^[18]

The use of fluoroscopy and stepwise increases of needle temperatures make this procedure relatively safe alternative. Most patients only need an overnight stay. Mortality is virtually nil and severe complications (cerebral hemorrhage, carotid-cavernous fistula, meningitis, and cranial nerve lesions) are very rare.^[19]

The largest review till date, Lee *et al.* reported the results for 1600 patients who had undergone percutaneous RF trigeminal rhizotomy over a period of 25 years. The complications reported in this large study were decreased corneal reflex (5.7%), weakness and paralysis of the masseter muscle (4.1%), dysesthesia (1%), anesthesia dolorosa (0.8%), keratitis (0.6%), and temporary paralysis of the third and fourth cranial nerves (0.8%). Complications like anesthesia dolorosa, though considered rare by some, are regarded to be worse than the initial pain of TN.^[20]

It was perhaps for this reason that PRF was explored as a less risky alternative. However, Erdine *et al.* demonstrated in a double-blinded trial that PRF was remarkably less efficacious than conventional RF. Their results demonstrate significant pain reductions in all patients treated with conventional RF, while only 2 of the 20 patients in the PRF group experienced this level of pain relief.^[21]

A systematic review of ablative neurosurgical techniques for the treatment of TN evaluated 166 studies reporting RF thermocoagulation, GR, BC of the trigeminal ganglion, and stereotactic radiosurgery and concluded that RF thermocoagulation offers the highest rates of complete pain relief.^[22]

In our opinion, RF trigeminal rhizotomy is still an invaluable technique that has provided pain relief for many patients with TN. In our opinion, PRF needs to be performed to a similar degree to be compared in the same light.^[23,24]

RF is suggested in the elderly because it is more beneficial to them in terms of low morbidity and mortality. Studies

show that RFL provided a high initial pain relief, with a pain-free rate of 50.4% after a 5-year follow-up. After 37 years of experience in the TN field and based on the results from their most recent study, Nicol concluded that TN is a lifelong disease that requires expert strategies with lifelong duration.^[25]

Study limitations

Many limitations in our study; as small sample size and short term follow up (only for one month). It is possible, for patients to self-report any untoward reaction that can mimic late-onset neuropathy, it was advisable to establish continuous follow-up using survey questionnaires and periodic checking for a longer period.

CONCLUSION

TGN is a lifelong disease that requires expert strategies with life-long duration of medical and surgical management, it is recommended that patients are offered psychological and nursing support. Neuroablative treatments may be preferred if magnetic resonance imaging does not demonstrate any neurovascular contact. RF is an effective, accurate, and precise procedure that provides efficient pain relief to TGN sufferers. RF is suggested in the elderly because it is more beneficial to them in terms of low morbidity and mortality.

Declarations

- The authors declare no conflicts of interest
- Consent for publication was taken from all included patients
- The study was done after local ethical committee approval of Assiut University Hospitals and written consent from all included patients
- The datasets used and/or analyzed during the current study are available from the corresponding author on reasonable request.

REFERENCES

1. Brisman R. Trigeminal neuralgia: Diagnosis and treatment. *World Neurosurg* 2011;76:533-4.
2. Bennetto L, Patel NK, Fuller G. Trigeminal neuralgia and its management. *BMJ* 2007;334:201-5.
3. Jannetta PJ, McLaughlin MR, Casey KF. Technique of microvascular decompression. Technical note. *Neurosurg Focus* 2005;18:E5.
4. Jannetta PJ, Tew JM Jr. Treatment of trigeminal neuralgia. *Neurosurgery* 1979;4:93-4.

5. Young RF, Vermulen S, Posewitz A. Gamma knife radiosurgery for the treatment of trigeminal neuralgia. *Stereotact Funct Neurosurg* 1998;70 Suppl 1:192-9.
6. Mullan S, Lichtor T. Percutaneous microcompression of the trigeminal ganglion for trigeminal neuralgia. *J Neurosurg* 1983;59:1007-12.
7. Håkanson S. Trigeminal neuralgia treated by the injection of glycerol into the trigeminal cistern. *Neurosurgery* 1981;9:638-46.
8. Sweet WH, Wepsic JG. Controlled thermocoagulation of trigeminal ganglion and rootlets for differential destruction of pain fibers. 1. Trigeminal neuralgia. *J Neurosurg* 1974;40:143-56.
9. Lopez BC, Hamlyn PJ, Zakrzewska JM. Systematic review of ablative neurosurgical techniques for the treatment of trigeminal neuralgia. *Neurosurgery* 2004;54:973-82.
10. Zakrzewska JM. Facial pain: Neurological and non-neurological. *J Neurol Neurosurg Psychiatry* 2002;72 Suppl 2:ii27-32.
11. Zakrzewska JM. Diagnosis and differential diagnosis of trigeminal neuralgia. *Clin J Pain* 2002;18:14-21.
12. Lord SM, Bogduk N. Radiofrequency procedures in chronic pain. *Best Pract Res Clin Anaesthesiol* 2002;16:597-617.
13. Punyani SR, Jasuja VR. Trigeminal neuralgia: An insight into the current treatment modalities. *J Oral Biol Craniofac Res* 2012;2:188-97.
14. Punyawudho B, Ramsay ER, Brundage RC, Macias FM, Collins JF, Birnbaum AK. Population pharmacokinetics of carbamazepine in elderly patients. *Ther Drug Monit* 2012;34:176-81.
15. Revuelta-Gutierrez R, Martinez-Anda JJ, Coll JB, Campos-Romo A, Perez-Peña N. Efficacy and safety of root compression of trigeminal nerve for trigeminal neuralgia without evidence of vascular compression. *World Neurosurg* 2013;80:385-9.
16. Meaney JF, Eldridge PR, Dunn LT, Nixon TE, Whitehouse GH, Miles JB. Demonstration of neurovascular compression in trigeminal neuralgia with magnetic resonance imaging. Comparison with surgical findings in 52 consecutive operative cases. *J Neurosurg* 1995;83:799-805.
17. Satoh T, Omi M, Nabeshima M, Onoda K, Date I. Severity analysis of neurovascular contact in patients with trigeminal neuralgia: Assessment with the inner view of the 3D MR cisternogram and angiogram fusion imaging. *AJNR Am J Neuroradiol* 2009;30:603-7.
18. Zhou Q, Liu Z, Li C, Qu C, Ni S, Zeng Q. Preoperative evaluation of neurovascular relationship by using contrast-enhanced and unenhanced 3D time-of-flight MR angiography in patients with trigeminal neuralgia. *Acta Radiol* 2011;52:894-8.
19. Vergani F, Panaretos P, Penalosa A, English P, Nicholson C, Jenkins A. Preoperative MRI/MRA for microvascular decompression in trigeminal neuralgia: Consecutive series of 67 patients. *Acta Neurochir (Wien)* 2011;153:2377-81.
20. Lee A, McCartney S, Burbidge C, Raslan AM, Burchiel KJ. Trigeminal neuralgia occurs and recurs in the absence of neurovascular compression. *J Neurosurg* 2014;120:1048-54.
21. Han-Bing S, Wei-Guo Z, Jun Z, Ning L, Jian-Kang S, Yu C. Predicting the outcome of microvascular decompression for trigeminal neuralgia using magnetic resonance tomographic angiography. *J Neuroimaging* 2010;20:345-9.
22. Leal PR, Hermier M, Froment JC, Souza MA, Cristino-Filho G, Sindou M. Preoperative demonstration of the neurovascular compression characteristics with special emphasis on the degree of compression, using high-resolution magnetic resonance imaging: A prospective study, with comparison to surgical findings, in 100 consecutive patients who underwent microvascular decompression for trigeminal neuralgia. *Acta Neurochir (Wien)* 2010;152:817-25.
23. Campbell FG, Graham JG, Zilkha KJ. Clinical trial of carbamazepine (tegretol) in trigeminal neuralgia. *J Neurol Neurosurg Psychiatry* 1966;29:265-7.
24. Killian JM, Fromm GH. Carbamazepine in the treatment of neuralgia. Use of side effects. *Arch Neurol* 1968;19:129-36.
25. Nicol CF. A four year double-blind study of tegretol in facial pain. *Headache* 1969;9:54-7.

How to cite this article: Elzohry AAM, Amin AM, Abdel-Wahab AT, Hassanin AAM. Medical Treatment versus Radiofrequency Ablation for Patients with Trigeminal Neuralgia: A Prospective Clinical Study. *Clin Res Neurol* 2019;2(2):1-5.