

# Multiple Intraocular Caterpillar Hairs

Anuja Mohanty, Santosh Kumar Mahapatra

*Department of Vitreoretina, JPM Rotary Eye Hospital and Research Institute, Cuttack, Orissa, India*

## ABSTRACT

**Aim:** This study aims to report an unusual case of non-subsiding intraocular inflammation due to the presence of intracamerar, intracorneal, intralenticular, and intravitreal caterpillar hairs. **Methods:** Here we present a case of non-subsiding intraocular inflammation for 3 months despite of using local and systemic steroids. The patient subsequently underwent B-scan ultrasonography and surgical removal of caterpillar hairs from intracamerar, intracorneal, and intravitreal locations. **Results:** Total subsidence of intraocular inflammation and improvement of visual acuity at 6 weeks follow up the following surgical removal. **Conclusion:** Unidentifiable intraocular caterpillar hairs could be an uncommon cause of non-resolving intraocular inflammation which needs to be meticulously surgically removed.

**Key words:** Caterpillar hair, caterpillar hair induced ophthalmitis, intraocular inflammation, pars plana vitrectomy

## PURPOSE

The purpose of the study was to present a case of non-subsiding intraocular inflammation with gross diminution of vision of more than 3 months duration due to the presence of multiple intraocular caterpillar (CP) hairs.

### Setting

A 19-year-old male presented to a tertiary eye care center in Eastern India with multiple intraocular caterpillar hairs. Here, we present a case of non-subsiding intraocular inflammation for more than 3 months with intracorneal, intracamerar, intralenticular, and intravitreal caterpillar hairs which were surgically removed successfully.

### Case

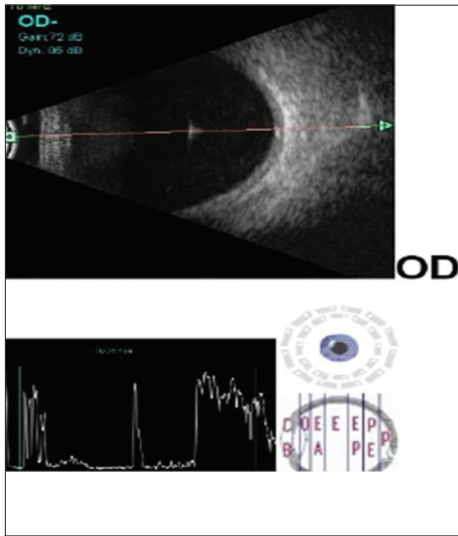
A 19-year-old male presented to our hospital with the complaints of pain, redness, and blurred vision in his right eye for 3 months. He was being treated with topical steroid for anterior uveitis during the same period, without any significant improvement. His best-corrected visual acuity was 5/60 and 6/6 in his right eye and left eye, respectively.

Examination of the left eye showed no abnormality. Slit-lamp examination of the right eye revealed corneal infiltrate at 7 o'clock position, Grade 2 cells, and flare in anterior chamber. Fundoscopy showed vitreous haze with a refractile structure in mid-vitreous cavity. B-scan revealed the presence of a thin linear foreign body in the vitreous cavity with a corresponding high spike echo suggestive of intravitreal caterpillar setae [Figure 1]. Further, examination revealed the presence of caterpillar hair in cornea at 7 o'clock, at 5 o'clock position in anterior chamber, and in lens at 8 o'clock position [Figure 2]. Caterpillar hair from the cornea and anterior chamber was removed under microscope in the same sitting of pars plana vitrectomy. The intracamerar caterpillar hair was grasped with vitreous forceps after filling anterior chamber with viscoelastic and removed through the side port [Figure 3]. The intravitreal caterpillar hair was removed with the vitrectomy cutter port as it was impossible to grasp the caterpillar hair with vitreous forceps. The intralenticular seta was left behind as it was inside the lens matter without causing any inflammation and the lens was clear. After the removal of multiple caterpillar setae, the patient was treated with topical and oral steroids. There was subsidence of inflammation with improvement in vision to

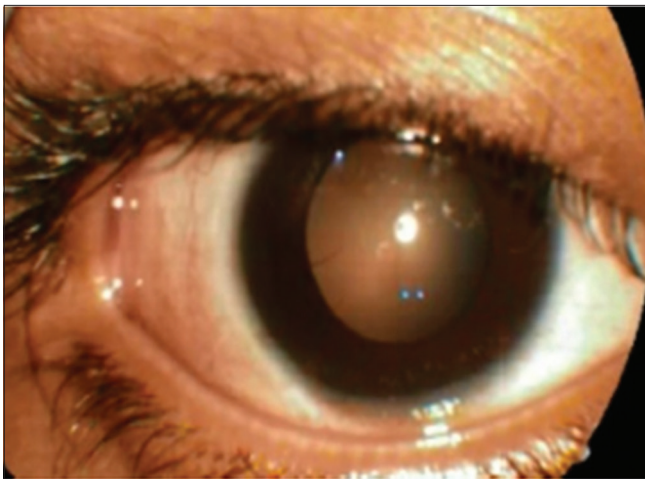
### Address for correspondence:

Dr. Santosh Kumar Mahapatra, Chief Medical Officer, JPM Rotary Eye Hospital and Research Institute, Sec-6, CDA, Cuttack, Orissa - 753 014, India. Phone: 06712363994. E-mail: santu\_k74@rediffmail.com

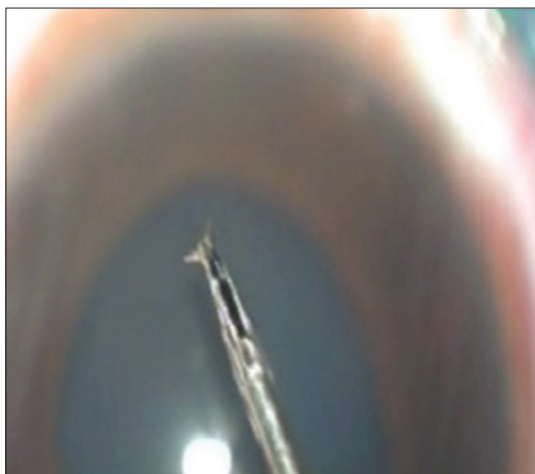
© 2019 The Author(s). This open access article is distributed under a Creative Commons Attribution (CC-BY) 4.0 license.



**Figure 1:** B-scan showing intravitreal CP hair with corresponding high hyper-reflective spike on A-scan overlay



**Figure 2:** Anterior segment photograph showing intralenticular CP hair at 8 o'clock position



**Figure 3:** Intracameral CP hair after removal from the anterior chamber

6/9 at the end of 6 weeks. He had no recurrence of intraocular inflammation and lens remained clear at 1 year of follow-up.

## DISCUSSION

The prevalence of caterpillar hair induced ophthalmitis (CHIO) is high in this part of the world as population is more exposed to agricultural circumstances. It is very difficult to remove the hair in all instances due to their extreme friability, accompanying corneal edema, surrounding infiltration, and deep-lying hair. Most patients have more than one hair, all of which may not be amenable for removal at the first sitting. Thus, patients with retained intracorneal hair must be followed up closely as vision-threatening complications may develop late in the course of the disease. Pathophysiology of inflammation is assumed to be both partially mechanical Lamy *et al.*<sup>[2]</sup> (progression caused by distal end oriented barbs on setae) and partly toxic<sup>[1-3]</sup> (thymopoinin secreted from the venom gland connected to the hair shaft). A number of theories have been postulated, suggesting possible mechanism of migration of setae.<sup>[4,5]</sup> Gundersen *et al.*<sup>[4]</sup> suggested that the setae have no propulsive power of their own, movements of the globe with versions, respirations, and pulse together with the constant iris movement propel the spines (on the setae) forward. It can be seen from the electron micrographs that the direction of the spines is vital in this, allowing only forward movements.

This case highlights the value of a careful ocular examination and proper history taking in a case of non-resolving uveitis which helped us to reach at an accurate diagnosis. The treatment emphasizes on meticulous removal of all caterpillar hairs along with anti-inflammatory medications as required. Phacoemulsification with steroid cover and periodic follow-up in the management of cataractous lens associated with intralenticular setae is of potential value in such eyes.

## CONCLUSION

Although caterpillar hairs on ocular surface are common, intraocular caterpillar hair is rare and intravitreal caterpillar hair is even rarer. CHIO is an inflammatory response of ocular tissue to caterpillar hair/other insect hairs that come in contact with the eye. It is usually an innocuous condition responding well to conservative management. However, in some cases, there is an intraocular penetration of CP hair resulting in uveitis, vitritis, and intralenticular abscess and even endophthalmitis which need careful observation and meticulous management.

## REFERENCES

1. Steele C, Lucas DR, Ridgway AE. Endophthalmitis due to caterpillar setae: Surgical removal and electron microscopic

- appearances of the setae. Br J Ophthalmol 1984;68:284-8.
2. Lamy M, Pastureaud MH, Novak F, Ducombs G, Vincendeau P, Maleville J, *et al.* Thaumetopoein: An urticating protein from the hairs and integument of the pine processionary caterpillar (*Thaumetopoea pityocampa* schiff. lepidoptera, thaumetopoeidae). Toxicon 1986;24:347-56.
  3. Horng CT, Chou PI, Liang JB. Caterpillar setae in the deep cornea and anterior chamber. Am J Ophthalmol 2000;129:384-5.
  4. Gundersen T, Heath P, Garron LK. Ophthalmia nodosa. Trans Am Ophthalmol Soc 1950;48:151-69.
  5. Ascher KW. Mechanism of locomotion observed on caterpillar hairs. Br J Ophthalmol 1968;52:210.

**How to cite this article:** Mohanty A, Mahapatra SK. Multiple intraocular caterpillar hairs. Clin Res Ophthalmol 2019;2(1):1-3.