

Hand-assisted Laparoscopy Nephrolithotomy on Staghorn Calculi: A Rare Case

Eriawan Agung Nugroho¹, Andy Supandi², Agnes Stella Valentina²

¹Department of Urology, Faculty of Medicine, Diponegoro University, Dr. Kariadi General Hospital, Semarang, Indonesia, ²General Surgery Resident, Faculty of Medicine, Diponegoro University, Dr. Kariadi General Hospital, Semarang, Indonesia

ABSTRACT

Staghorn calculi remain a challenging problem for urologists although most cases of renal calculi are managed successfully with extracorporeal shockwave lithotripsy and percutaneous nephrolithotomy. Open surgery is reserved for complex renal stone conditions although is invasive in nature. Laparoscopic surgery has several advantages over open surgery including low morbidity rate; moreover, several studies show that laparoscopic surgery is feasible for urological conditions. We reported a 56-year-old male with staghorn calculi with severe hydronephrosis on the left renal managed with hand-assisted laparoscopic nephrolithotomy with a great outcome.

Key words: Staghorn calculi, hand-assisted laparoscopy nephrolithotomy, hydronephrosis

INTRODUCTION

Staghorn calculi are characterized with large branching calculi filled renal pelvis and calyces, and usually unilateral. It forms 10–20% of the entire urinary stones. Staghorn stones are usually get infected and potentially cause morbidity and mortality. Management of staghorn calculi remains a challenge in urology.^[1]

Percutaneous nephrolithotomy (PNL) is widely accepted as the standard procedure for staghorn calculi. Thus, open nephrolithotomy once was the preferred approach to staghorn stones, is now reserved for complex problems where complicated factors make PNL impossible or unlikely to achieve reasonable stone clearance.^[2,3]

Laparoscopic surgery provides several benefits over open surgery including shorter length of hospital stay, less post-operative pain, and faster recovery periods. However, the number of studies regarding the role of laparoscopic management of staghorn calculi is quite limited.^[4,5] We

reported a staghorn calculi managed with hand-assisted laparoscopy nephrolithotomy.

CASE REPORT

A 56-year-old male came to urology clinic with history of intermittent left flank pain and recurrent urinary tract infections. These symptoms had been felt for the past 2 weeks. He felt dull pain radiating from his left abdomen to his left flank. He also complained of reddish urine and a lump in his left abdomen. The patient had received antibiotics and painkillers for recurrence urinary tract infections for the past 1 year. Approximately 2 months ago, he felt lump on his left abdomen getting bigger, he went to urology clinic, and an abdominal computed tomography (CT) scan [Figure 1] was done with severe hydronephrosis on the left renal with renal stone. The patient had no history of another disease before.

Physical examination on his abdomen, we found a lump with diameter ±3 cm, hard, fixated, and tenderness. Cost over

Address for correspondence:

Andy Supandi, General Surgery Resident, Faculty of Medicine, Diponegoro University, Dr. Kariadi General Hospital, Semarang, Indonesia. E-mail: andysupandi87@gmail.com

© 2019 The Author(s). This open access article is distributed under a Creative Commons Attribution (CC-BY) 4.0 license.

tubal angle percussion was positive in the left side. Genital was normal.

Laboratory findings showed blood counts, renal, and liver function were within normal limit. Urinalysis showed pH of 8.1; in urine sediments, there were 10 cells erythrocytes per field of view and presence of calcium oxalate crystals. Abdominal CT with contrast showed left staghorn calculi with severe hydronephrosis on the left kidney.

The patient then treated with proper antibiotic and underwent hand-assisted laparoscopy nephrolithotomy [Figure 2] for calculi removal. We successfully extracted multiple large renal calculi [Figure 3]. The largest stone was 4 cm in diameter [Figure 4]. The patient was discharged on day 6 after operation and did not show any signs of complications. The post-operative wound remained well and no significant inflammation was observed. During follow-up (1 week later), patient remained symptom-free.

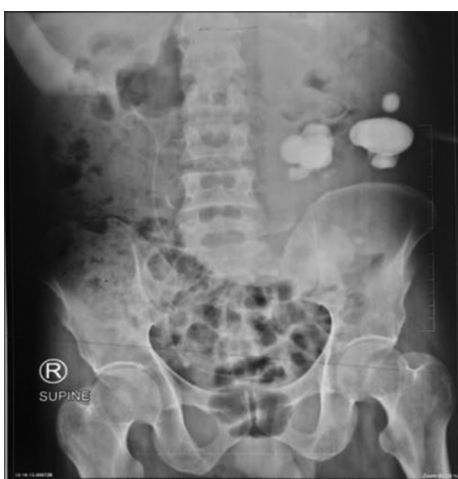

Figure 1: Plain abdominal radiograph showed large, multiple renal calculi

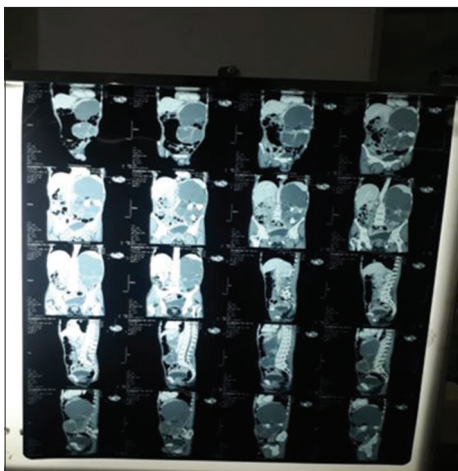


Figure 2: Abdominal computed tomography scan

DISCUSSION

The treatment of staghorn calculi remains challenging. The goal of the treatment is to achieve complete removal of stone (because the stone likely to regrowth), preservation of renal function, eradication of infections, and relieve from obstruction. The stone-free status may require several procedures and might result morbidity. Therefore, open surgery is reserved as last option for managing large staghorn calculi.^[2]

In this case, we identify a middle-aged male patient with a history of recurrence of urinary tract infection as an underlying factor for staghorn calculi. He had received antibiotics medication repeatedly for his complaint. He came to our hospital due to pain in his left abdomen radiating to his left flank. His urinalysis showed alkali urine with pH of 8.1; in urine sediments, there were 10 cells erythrocytes per field of view and presence of calcium oxalate crystals. This alkali urine supports the formation of struvite calculi and responsible for repeated urinary infections.^[2] Leukocyte and nitrite were negative on urinalysis might be due to his long-term antibiotic medication. CT scan was used in diagnosing the presence of staghorn calculi and severe hydronephrosis on the left renal.

We considered hand-assisted nephrolithotomy is superior to PNL in stone extraction and less invasive compared to

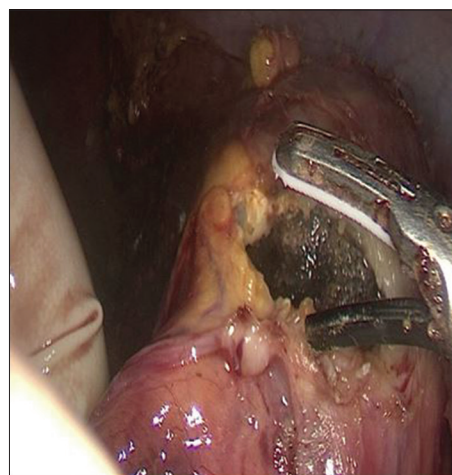


Figure 3: Extraction of staghorn calculi with hand-assisted nephrolithotomy

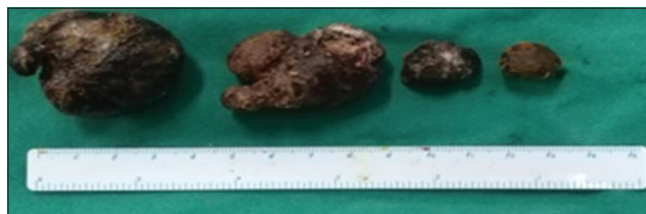


Figure 4: Gross picture of removed renal calculi

open nephrolithotomy. This procedure also has another advantage of avoiding vascular complications secondary to renal parenchyma puncture; hence, it is safe and minimizes blood loss. We successfully extracted multiple large stones; the largest extracted calculi measured were 4 cm in diameter with minimal bleeding. The patient was discharged on day 6 and did not show any signs of complications. This showed the advantage of hand-assisted laparoscopic nephrolithotomy in this patient; this patient had minimal blood loss intraoperative (drain production was minimum in the 2nd day post-operative) due to minimal renal parenchyma puncture.

Complete stone removal is the main objective for staghorn calculi. Eradication of the associated urinary tract infection is only possible after the stone has been completely removed since stone contains bacteria despite antibiotic medication.

CONCLUSION

Renal stone diseases, especially staghorn calculi, are tightly related to urinary tract infection. Appropriate management of staghorn calculi and risk factors must be wisely taken to prevent morbidity, further complications, and recurrent emergence of the renal stone. Hand-assisted laparoscopic nephrolithotomy might offer an alternative for large renal stone removal due to its capability of complete large

renal stone removal and less invasive compared to open nephrolithotomy.

REFERENCES

1. Diri A, Diri B. Management of staghorn renal stones. *Ren Fail* 2018;40:357-62.
2. Wein AJ, Kavoussi LR, Partin AW, Peters CA. Urinary lithiasis. In: *Campbell-Walsh Urology*. 11th ed., Vol. 2., Ch. 51. Amsterdam: Elsevier; 2016. p. 1170-234.
3. McAninch JW, Lue TF. Percutaneous endourology and ureterorenoscopy. In: *Smith and Tanagho's General Urology*. 18th ed., Ch. 8. New York: McGraw Hill; 2013. p. 112-29.
4. Basiri A, Tabibi A, Nouralizadeh A, Arab D, Rezaeetalab GH, Hosseini Sharifi SH, *et al.* Comparison of safety and efficacy of laparoscopic pyelolithotomy versus percutaneous nephrolithotomy in patients with renal pelvic stones: A randomized clinical trial. *Urol J* 2014;11:1932-7.
5. Richard P, Bettez M, Martel A, Ponsot Y, Sabbagh R. Laparoscopic management of a large staghorn stone. *Can Urol Assoc J* 2012;6:E121-4.

How to cite this article: Nugroho EA, Supandi A, Valentina AS. Hand-assisted Laparoscopy Nephrolithotomy on Staghorn Calculi: A Rare Case. *Clinic Res Urol* 2019;2(2):1-3.