

# Triad of Hyperparathyroidism, Hypercalcemia and the Heart: Hyperparathyroidism: Licks the Body, Blocks the Heart!

Ajay Mishra<sup>1</sup>, Sonia Mishra<sup>2</sup>, J. P. Mishra<sup>2</sup>

<sup>1</sup> Georgetown University, Washington, DC 20057, USA, <sup>2</sup>Department of Upstate Cardiology, 215 Summit St, Batavia, New York 14020, USA

## ABSTRACT

We present a case of a 70-year-old lady with a known history of hypertension and dyslipidemia came in for cardiac consult due to known slow pulse and occasional dizziness and lightheadedness. We review the literature of hyperparathyroidism, hypercalcemia, and their effects on the heart.

**Key words:** Arrhythmia, Atrioventricular block, hypercalcemia, hyperparathyroidism

## INTRODUCTION

Primary hyperparathyroidism (PHPT) is a common endocrine disorder occurs in about 0.1–0.3% of the population, most commonly caused by a single parathyroid adenoma (85%), occasionally by parathyroid glandular hyperplasia (15%) and rarely by parathyroid carcinoma (<1%).<sup>[1]</sup> Most commonly it begins in the 3<sup>rd</sup>–5<sup>th</sup> decades of life and it is 2–3 times more common in women compared to men.

Most patients with hyperparathyroidism will have associated hypercalcemia, and most of the symptoms of hyperparathyroidism are related to hypercalcemia.

We present a case of a 70-year-old lady with hypertension, dyslipidemia, and slow pulse that has been diagnosed with hyperparathyroidism and hypercalcemia. Thereafter, we review the pertinent literature of association of hyperparathyroidism and hypercalcemia and their effects on the heart.

## CASE REPORT

A 70-year-old lady presented to our office for cardiac evaluation with a history of “slow pulse.” She has a history

of hypertension and dyslipidemia and was noted to have her pulse in 40 s since October 2017. She complained of being dizzy and lightheaded at times, however able to keep her job. She gave a history of rheumatic fever during her childhood. She saw her internist and was advised for cardiac evaluation given her slow heart rate. Her blood pressure was 158/72 mmHg with a pulse of 52 beats/min. Her cardiac examination was unremarkable except a soft Grade II/VI systolic murmur at the left parasternal border.

Her recent blood test showed most parameters being normal except calcium level of 10.6 mg/dl and parathyroid hormone (PTH) level of 93.5 pg/cc.

Her 12-lead electrocardiogram (EKG) and rhythm strip in the office were taken [Figures 1 and 2]. A two-dimensional (2D)-echocardiographic study and a Holter monitor were requested. A parathyroid nuclear scan and an endocrinology consult were pending.

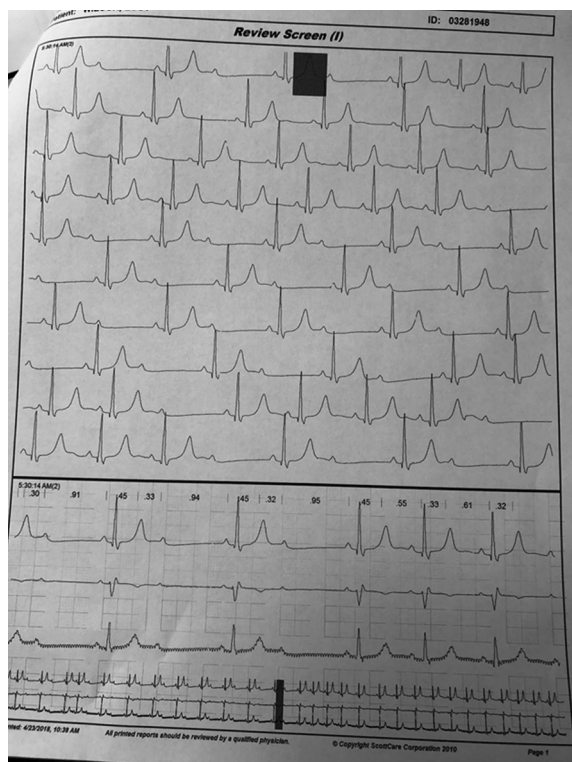
### Holter monitor study report

His 24-h Holter monitor showed sinus bradycardia and frequent 2:1 atrioventricular (AV) conduction without any dizziness, presyncope, or syncope. A sample copy is shown here.

### Address for correspondence:

J. P. Mishra, Upstate Cardiology, 215 Summit St, Batavia, New York 14020, USA. E-mail: jpmish@gmail.com

© 2018 The Author(s). This open access article is distributed under a Creative Commons Attribution (CC-BY) 4.0 license.



### 2D-Echocardiographic findings

Preserved left ventricular (LV) systolic function with LV ejection fraction (LVEF) of 60%. No significant valvular dysfunction. No evidence of pulmonary hypertension or pericardial effusion.

### Parathyroid nuclear scan report

There is no evidence of parathyroid adenoma. The scan was reported to be normal.

## DISCUSSION

### Hyperparathyroidism

The primary effect of PTH is to increase plasma calcium by increasing the release of calcium and phosphate from bone matrix, increasing calcium reabsorption by the kidney, and increasing renal production of 1,25-dihydroxy Vitamin D3 (calcitriol) which increases intestinal absorption of calcium. Therefore, increased PTH (hyperparathyroidism) results in elevated levels of plasma calcium (hypercalcemia) while decreasing serum phosphorus.

### PHPT

This condition is due to the uncontrolled overproduction of PTH resulting in abnormal calcium homeostasis.

### Secondary hyperparathyroidism

This is due to the increased production of PTH secondary to hypocalcemia, mostly because of Vitamin D deficiency and/

or chronic kidney disease.

### Tertiary hyperparathyroidism

This is a state of increased production of PTH after long-standing secondary hyperparathyroidism and resulting in hypercalcemia. Some endocrinologists reserve this entity for secondary hyperparathyroidism that persists after a successful kidney transplant.

Our review will mostly focus on PHPT, hypercalcemia, and their effects on the cardiovascular system.

Most of the symptoms of hyperparathyroidism are secondary to hypercalcemia. Hyperparathyroidism is the most common cause of hypercalcemia; however, there are many causes of hypercalcemia that can be remembered by the mnemonic: Chimpanzee's (2): Calcium excess (administration), hyperparathyroidism, immobility/iatrogenic, metastasis/milk-alkali syndrome, Paget's disease, Addison's disease, Neoplasms, Zollinger Ellison syndrome, Excess Vitamin D, Excess Vitamin A, and sarcoidosis.

Hypercalcemia can affect many organs in the body, however mostly involving kidneys, Skeletal, GI, neuromuscular, and cardiovascular systems. These symptoms can be nausea, constipation, renal stones, pancreatitis, polyuria, bone pains, psychiatric symptoms, and all these can be remembered by the mnemonic: "Stones, groans, moans, and psychiatric overtones."<sup>[2]</sup>

### Hyperparathyroidism and the heart

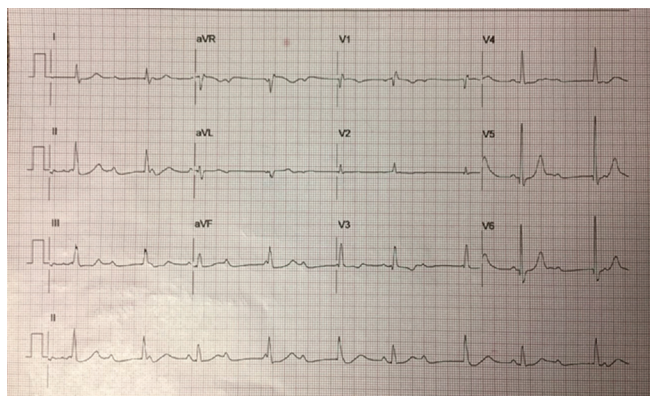
The common denominator in this disease is hypercalcemia. In Western Europe and USA, the diagnosis of hyperparathyroidism and hypercalcemia can be made early on and thus patients may be asymptomatic. However, in the rest of the world, by the time it is a diagnosis, it can be quite late with various symptoms.<sup>[3]</sup> If the patients are symptomatic from PHPT, there is increase mortality before and after parathyroidectomy, and mostly it appears to be so due to cardiovascular death.<sup>[4]</sup>

The cardiovascular effects of hypercalcemia may include hypertension, left ventricular hypertrophy (LVH), arrhythmia, vascular calcification, and possibly increased mortality.

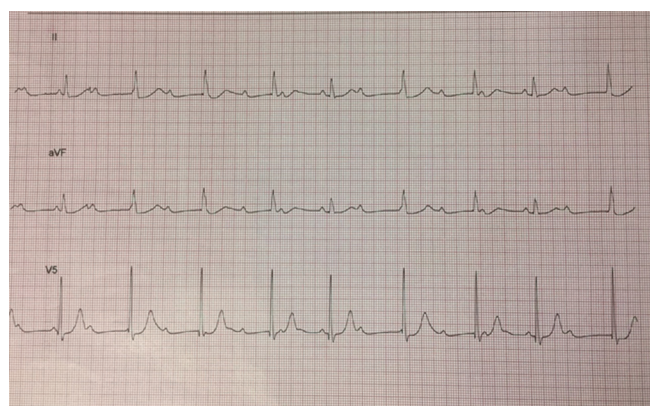
Hypercalcemia can be associated with LVH, along with effects on myocardial interstitium, the conducting system (arrhythmia), calcific deposition on the valves and annuli and structural and functional alterations in the vascular wall.<sup>[5,6]</sup> Severe hypercalcemia is associated with valvular and myocardial calcification whereas mild/moderate hypercalcemia might not.

### Hypertension and LVH

It is presumed that serum calcium can cause hypertension



**Figure 1:** Sinus rhythm, right bundle branch block, advanced 2:1 atrioventricular (AV) conduction/block versus transient AV block



**Figure 2:** Rhythm strip of the same patient same time

by its effect on smooth muscle vasoconstriction, increased calcium ion influx, and increased vascular resistance. There could be increased catecholamine release in these patients contributing to hypertension.

LVH is reported in patients with PHPT. PTH can act on cardiomyocytes and cause an increase in LV mass by increasing an intracellular calcium level which can then activate protein kinase C and cause hypertrophic as well as metabolic effects on the myocardium.<sup>[7]</sup> Increased PTH can also contribute to LVH by direct positive chronotropic effects and mediated inotropic effects on the heart.<sup>[8]</sup> LVH can regress in some patients after 1–2 years after parathyroidectomy; however, no regression is seen in many other patients.<sup>[9]</sup> In one study, patients randomized to parathyroidectomy at baseline did not develop further LVH compared to the group treated conservatively for a year before surgery.<sup>[10]</sup>

It is not quite clear whether the increase in PTH or calcium or the calcium phosphate product is responsible for cardiac changes. Preliminary studies show that both PTH and elevated calcium have hypertrophic effects on cardiomyocytes.<sup>[11]</sup> However, another study has shown that PTH augments the

entry of calcium into tissues independent of serum calcium level and PTH maintains the LVH progression, and thus cardiac hypertrophy is related to PTH and not to hypercalcemia.<sup>[12]</sup>

### LV systolic function

LV systolic function is usually not affected in patients with PHPT. Most of the parameters are reported to be unaffected including LVEF, LV ejection time, fractional shortening, cardiac index, and LV end-systolic volume.<sup>[8]</sup> One very small study reported a small decrease in LVEF,<sup>[13]</sup> while another smaller study reported an increase in cardiac output in these patients.<sup>[14]</sup>

### LV diastolic dysfunction

Because of increased likelihood of LVH, myocardial calcification, and hypertension, there is a greater chance of diastolic dysfunction in patients with PHPT. A few studies have shown reduced E/A ratio of transmitral peak flow velocity (Doppler-derived early [E] and late [A] atrial contraction).<sup>[15]</sup>

A prolonged isovolumetric relaxation time, indicating diastolic filling impairment, an indicator of diastolic dysfunction has been found in some studies of PHPT patients.<sup>[16]</sup> However, there are also smaller studies showing no effects on diastolic function in these patients;<sup>[17]</sup> therefore, this issue is far from being settled at this point.

### Valvular calcifications

There are several studies indicating increased calcifications involving the mitral and the aortic valves. The calcification has been confirmed by 2D-echocardiographic studies. Many of these patients also have associated myocardial calcifications.<sup>[18,19]</sup> Asymptomatic patients may have mild hyperparathyroidism and mild hypercalcemia. In addition, there are also some smaller studies reporting no increase in calcifications.<sup>[5]</sup>

### Increased mortality

There are a number of studies by now confirming the increased mortality in symptomatic PHPT patients, and the mortality can be increased before or even after parathyroidectomy in these cases.<sup>[20-22]</sup> In many patients, this increase in mortality is likely due to cardiovascular death; however, no obvious cardiac parameter has been found responsible for this increase. In some cases with PHPT, hypercalcemia has been associated with an increased likelihood of myocardial infarction.<sup>[23,24]</sup>

It is still unclear whether asymptomatic PHPT patients have an increased risk of cardiac disease or mortality whereas most mortality studies have shown an increased risk of death.

### Arrhythmia

It is well known that serum calcium levels correlate



positively with T wave duration and negatively with QT and QT interval (QTc) interval. The duration of the plateau of the action potential of cardiomyocyte is shortened by high serum calcium concentration. There are conflicting reports in the literature whether hypercalcemia is related to clinically relevant conduction disturbances or not. It has been shown that mild/moderate hypercalcemia may not be associated with increased likelihood of ventricular or supraventricular arrhythmia or high-grade AV block.<sup>[25]</sup> However, one study has demonstrated that PHPT could cause sinus node dysfunction.<sup>[26]</sup>

ECG manifestations of hypercalcemia include a shortened ST segment leading to a short corrected QTc, slight increase in T wave duration and rarely, and Osborn waves or J waves.<sup>[27]</sup> However, its influence leading to advanced AV conduction issues or complete heart blocks is not well known. One study reported severe bradycardia in a patient with breast carcinoma and acute hypercalcemia due to bone metastases.<sup>[28]</sup>

There is a case report of malignancy-related severe hypercalcemia leading to complete heart block which resolved after treating hypercalcemia.<sup>[29]</sup>

The pathophysiology of hypercalcemia-induced AV nodal conduction system disease is unclear. On a chronic basis, calcium deposition in AV nodes of elderly patients can lead to paroxysmal 2:1 AV block; however, the mechanism in an acute setting of hypercalcemia could be different.<sup>[30]</sup>

There is obviously need for much more research in the field of hyperparathyroidism, hypercalcemia, and their role in cardiac abnormalities including hypertension, LVH, mortality, and cardiac arrhythmia.

## CONCLUSION

Our patient eventually became symptomatic from advanced AV conduction disease with recurrent dizziness and presyncope requiring pacemaker implantation. She is doing well since then.

Hyperparathyroidism is an otherwise rare disease. However, the suspicion index has to be high especially in patients found to have hypercalcemia, abnormal EKG, and arrhythmia including AV conduction disease.

## REFERENCES

1. Fernandez-Ranvier GG, Khanafshar E, Jensen K, Zarnegar R, Lee J, Kebebew E, *et al.* Parathyroid carcinoma, atypical parathyroid adenoma, or parathyromatosis? *Cancer* 2007;110:255-64.
2. Stoelting RK. Handbook for Stoelting's Anesthesia and

- Co-Existing Disease. 4<sup>th</sup> ed. Philadelphia, PA: Elsevier/Saunders. 2013.
3. Heath DA. Primary hyperparathyroidism. Clinical presentation and factors influencing clinical management. *Endocrinol Metab Clin North Am* 1989;18:631-46.
4. Hedbäck G, Odén A. Increased risk of death from primary hyperparathyroidism—an update. *Eur J Clin Invest* 1998;28:271-6.
5. Nuzzo V, Tauchmanová L, Fonderico F, Trotta R, Fittipaldi MR, Fontana D, *et al.* Increased intima-media thickness of the carotid artery wall, normal blood pressure profile and normal left ventricular mass in subjects with primary hyperparathyroidism. *Eur J Endocrinol* 2002;147:453-9.
6. Bukoski RD, Ishibashi K, Bian K. Vascular actions of the calcium-regulating hormones. *Semin Nephrol* 1995;15:536-49.
7. Schlüter KD, Piper HM. Trophic effects of catecholamines and parathyroid hormone on adult ventricular cardiomyocytes. *Am J Physiol* 1992;263:H1739-46.
8. Näppi S, Saha H, Virtanen V, Linnell V, Sand J, Salmi J, *et al.* Left ventricular structure and function in primary hyperparathyroidism before and after parathyroidectomy. *Cardiology* 2000;93:229-33.
9. Almqvist EG, Bondeson AG, Bondeson L, Nissborg A, Smedgård P, Svensson SE, *et al.* Cardiac dysfunction in mild primary hyperparathyroidism assessed by radionuclide angiography and echocardiography before and after parathyroidectomy. *Surgery* 2002;132:1126-32.
10. Buser PT, Wikman-Coffelt J, Wu ST, Derugin N, Parmley WW, Higgins CB, *et al.* Posts ischemic recovery of mechanical performance and energy metabolism in the presence of left ventricular hypertrophy. A 31P-MRS study. *Circ Res* 1990;66:735-46.
11. Symons C, Fortune F, Greenbaum RA, Dandona P. Cardiac hypertrophy, hypertrophic cardiomyopathy, and hyperparathyroidism—an association. *Br Heart J* 1985;54:539-42.
12. Barletta G, De Feo ML, Del Bene R, Lazzeri C, Vecchiarino S, La Villa G, *et al.* Cardiovascular effects of parathyroid hormone: A study in healthy subjects and normotensive patients with mild primary hyperparathyroidism. *J Clin Endocrinol Metab* 2000;85:1815-21.
13. Georgiannos SN, Jenkins BJ, Goode AW. Cardiac output in asymptomatic primary hyperparathyroidism: A stigma of early cardiovascular dysfunction? *Int Surg* 1996;81:171-3.
14. Dalberg K, Brodin LA, Juhlin-Dannfelt A, Farnebo LO. Cardiac function in primary hyperparathyroidism before and after operation. An echocardiographic study. *Eur J Surg* 1996;162:171-6.
15. Nilsson IL, Aberg J, Rastad J, *and others.* Left ventricular systolic and diastolic function and exercise testing in primary hyperparathyroidism – effects of parathyroidectomy. *Surgery* 2000;128:895-902.
16. Piovesan A, Molineri N, Casasso F, Emmolo I, Ugliengo G, Cesario F, *et al.* Left ventricular hypertrophy in primary hyperparathyroidism. Effects of successful parathyroidectomy. *Clin Endocrinol (Oxf)* 1999;50:321-8.
17. Stefanelli T, Mayr H, Bergler-Klein J, Globits S, Woloszczuk W, Niederle B, *et al.* Primary hyperparathyroidism: Incidence of cardiac abnormalities and partial reversibility after successful parathyroidectomy. *Am J Med* 1993;95:197-202.

18. Längle F, Abela C, Koller-Strametz J, Mittelböck M, Bergler-Klein J, Stefenelli T, *et al.* Primary hyperparathyroidism and the heart: Cardiac abnormalities correlated to clinical and biochemical data. *World J Surg* 1994;18:619-24.
19. Lundgren E, Lind L, Palmér M, Jakobsson S, Ljunghall S, Rastad J, *et al.* Increased cardiovascular mortality and normalized serum calcium in patients with mild hypercalcemia followed up for 25 years. *Surgery* 2001;130:978-85.
20. Sivula A, Ronni-Sivula H. Natural history of treated primary hyperparathyroidism. *Surg Clin North Am* 1987;67:329-41.
21. Udén P, Tibblin S. Mortality in patients surgically treated for primary hyperparathyroidism due to solitary adenoma. *Ann Chir Gynaecol* 1990;79:123-8.
22. Vestergaard P, Møllerup CL, Frøkjær VG, Christiansen P, Blichert-Toft M, Mosekilde L, *et al.* Cardiovascular events before and after surgery for primary hyperparathyroidism. *World J Surg* 2003;27:216-22.
23. Lind L, Skarfors E, Berglund L, Lithell H, Ljunghall S. Serum calcium: A new, independent, prospective risk factor for myocardial infarction in middle-aged men followed for 18 years. *J Clin Epidemiol* 1997;50:967-73.
24. Rosenqvist M, Nordenström J, Andersson M, Edhag OK. Cardiac conduction in patients with hypercalcaemia due to primary hyperparathyroidism. *Clin Endocrinol (Oxf)* 1992;37:29-33.
25. Shah AP, Lopez A, Wachsner RY, Meymandi SK, El-Bialy AK, Ichiuji AM, *et al.* Sinus node dysfunction secondary to hyperparathyroidism. *J Cardiovasc Pharmacol Ther* 2004;9:145-7.
26. Bronsky D, Dubin A, Waldstein SS, Kushner DS. Calcium and the electrocardiogram II. The electrocardiographic manifestations of hyperparathyroidism and of marked hypercalcemia from various other etiologies. *Am J Cardiol* 1961;7:833-9.
27. Badertscher E, Warnica JW, Ernst DS. Acute hypercalcemia and severe bradycardia in a patient with breast cancer. *CMAJ* 1993;148:1506-8.
28. Thotakura, S, Stafford J, Barnett B, Slicker K, Kramer D, Gupta R. Complete AV nodal block due to malignancy-related hypercalcemia. *Fed Pract* 2016;33:23-5.
29. Vosnakidis A, Polymeropoulos K, Zarogoulidis P, Zarifis I. Atrioventricular nodal dysfunction secondary to hyperparathyroidism. *J Thorac Dis* 2013;5:E90-2.
30. Silverberg SJ. Editorial: Cardiovascular disease in primary hyperparathyroidism. *J Clin Endocrinol Metab* 2000;85:3513-4.

**How to cite this article:** Mishra A, Mishra S, Mishra JP. Triad of Hyperparathyroidism, Hypercalcemia and the Heart: Hyperparathyroidism: Licks the Body, Blocks the Heart! *J Clin Cardiol Diagn* 2018;1(1):1-5.